



Accuracy of Ultrasound as a Diagnostic Tool for the Assessment of Occult Groin Hernias

Ajogwu Ugwu^{1,2,*}, Khurram Shahzad Khan³, Kit Chow⁴

¹Department of Surgery, University Hospital Wishaw, Wishaw, UK

²School of Medicine, University of Dundee, Dundee, UK

³Department of Surgery, NHS Greater Glasgow & Clyde, Glasgow, UK

⁴Department of Radiology, Sherwood Forest Hospitals, Nottinghamshire, UK

Email address:

ajogwuugwu@yahoo.ca (A. Ugwu), mrksk007@hotmail.com (K. S. Khan), kit.chow@doctors.org.uk (K. Chow)

*Corresponding author

To cite this article:

Ajogwu Ugwu, Khurram Shahzad Khan, Kit Chow. Accuracy of Ultrasound as a Diagnostic Tool for the Assessment of Occult Groin Hernias. *Journal of Surgery*. Vol. 8, No. 1, 2020, pp. 38-42. doi: 10.11648/j.js.20200801.18

Received: November 29, 2019; **Accepted:** December 23, 2019; **Published:** March 3, 2020

Abstract: Groin hernias are a common reason to attend general surgical clinic with over 71,000 groin hernia repairs carried out in England in 2014/15. Diagnosis of groin hernias is primarily a clinical one, but a significant proportion of them are symptomatic and are not clinically palpable. There are a number of investigative options available which includes herniography, ultrasound, CT and MRI. Herniography is invasive and less sensitive to diagnose occult hernias and some radiologist would consider it, unethical & obsolete. MRI and CT scan are expensive and not always available. We evaluated the role of ultrasound in the surgical management of a cohort of patients with clinically occult groin hernia in a district general hospital. A retrospective list of patients having ultrasound examination for symptomatic groin collected from radiology department. Ultrasound which confirmed presence of hernias were identified. Ultrasound findings and clinical assessment were analyzed. In patients who underwent surgery, intra-operative findings were taken as gold standard and compared with ultrasound results. Total number of hernias included in the study was 68. Male to female distribution of patients was 3.3; 1. The mean age of participants was 42 years. In 93%, the presenting symptoms were pain, lump or combination of both. 40 patients (59%) were operated from which there was PPV of 0.90 with intraoperative findings congruent with intraoperative findings. Ultrasound is non-invasive and non-ionizing radiation imaging modality for diagnosis of impalpable groin hernias with a PPV of 90%. Morbidity associated with this modality is low. It is readily available and cheaper than MRI and CT scan with no harmful ionization radiation thereby conferring a cost benefit as well. We have shown ultrasound is a suitable tool for the initial imaging investigation of occult clinically non-palpable hernia. Our review of current literature has shown wide variance of the choice of imaging technique and the accuracy of their published report.

Keywords: Groin Hernia, Femoral Hernia, Inguinal Hernia, Occult Hernia, Ultrasound

1. Introduction

Groin hernias are one of the most common reasons to attend a general surgical clinic and accounts for 71,000 groin hernia repairs in England in 2014/15 [1]. In 2016/2017 there were 78,733 inguinal hernia procedures carried out in hospitals in England, an increase of 0.8% from 2015/2016 [2]. Worldwide, inguinal hernia repair is one of the most common surgeries, performed on more than 20 million people annually [3]. Groin hernias are surgically correctable but failure to manage this

appropriately can lead to significant economic consequences. Historically, the diagnosis of a groin hernia has been clinical. With the development of highly sophisticated imaging techniques, these facilities are now greatly utilised to aid and improve the surgical management of hernia.

Despite good clinical acumen, a proportion of hernias are symptomatic but clinically not palpable. The British Hernia Society in collaboration with the Royal College of Surgeons of England published the commissioning guide in 2016 on groin hernia which recommends a dynamic ultrasound scan

(USS) as the first line investigation in diagnostic uncertainty [1]. The use of herniography is advised if USS is unavailable and there is local expertise.

Magnetic resonance imaging (MRI) is recommended if USS is negative & groin pain still persists & to exclude other causes of groin pain. This guide also highlights the fact that medical imaging is not to be arranged at primary care level. Ultrasound is non-invasive and readily available, but it is operator dependent.

Herniography is invasive with complications such as bowel injury, bleeding, infection with possibility of peritonitis and radiation risk. Herniography is now an extremely rare procedure. Some radiologist would consider it, unethical and obsolete. Other more modern methods of imaging have lower morbidity and similar accuracy.

MRI is expensive with no radiation risk, but it is not always available and there is a 10% incidence of examination failure due to claustrophobia.

The primary outcome of this study was to determine the role of ultrasound in the surgical management of this group of patients.

2. Methods & Materials

2.1. Prospective Subject Collection & USS Imaging Modality

A prospective list of patients from the radiology database

having had ultrasound examination for symptomatic groin hernia was collected from radiology department (n=268) for the period January 2010 – December 2010.

All USS were performed by a consultant radiologist with interest in ultrasound. All scans were performed initially in a supine position and sometimes supplemented with erect posture in selected patients. Valsalva manoeuvre was used to aid the dynamic assessment of the groin hernia.

2.2. Inclusion & Exclusion Criteria

Inclusion criteria included positive hernia on ultrasound (n=68). Exclusion criteria was negative hernia on USS (n=194) & non-availability of case notes (n=6). The total number of hernias included in the study was thus (n=68). Of the patients selected, 5 were recurrent hernia & 3 had bilateral hernias.

2.2.1. Data Analysis

Clinical assessment and findings, ultrasound findings, operative findings and follow-up were analysed. In patients who underwent surgery, intra-operative findings were taken as gold standard & definite confirmation of pathology and compared with ultrasound results. The intra-operative assessment was that of the most senior surgeon scrubbed in theatre, which was a consultant surgeon in all the cases. Follow-up was mainly based on clinical grounds i.e. surgical concerns post operatively & patient concerns. (See Figures 1 & 2)

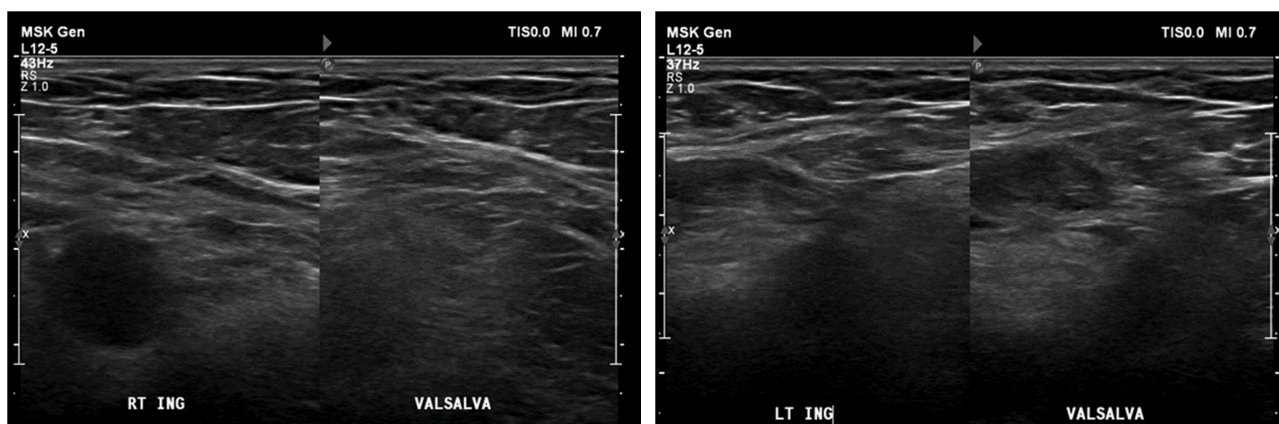


Figure 1. USS of inguinal region with findings of a negative scan performed using Valsalva manoeuvre.

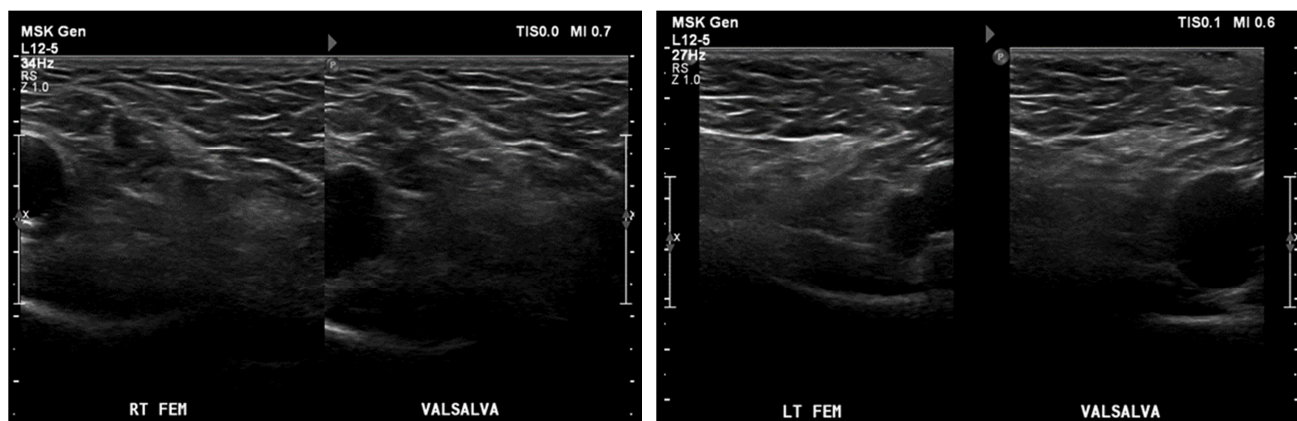


Figure 2. USS of femoral region with findings of a negative scan performed using Valsalva manoeuvre.

3. Results

The distribution of patients was M 3.3; F 1. The mean age of participants was 42 years (18–79 years). (See Figure 3).

In 93%, the presenting symptoms were pain, lump or combination of both. Pain was by far the most common presenting complaint with about 61% of cases.

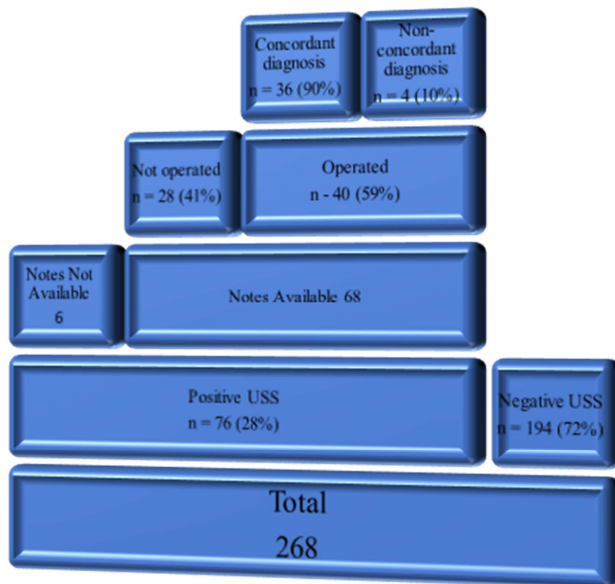


Figure 3. Schematic representation of patients collected from radiology database retrospectively who had ultrasound to investigate occult hernia.

	Ultrasound Findings	Operative Findings
1	Right Spigelian Hernia 1cm above the superior pubic ramus & lateral to inferior epigastric vessels.	Right Direct inguinal Hernia
2	Small right direct inguinal hernia.	Lipoma of cord
3	Small right femoral hernia.	No hernia on exploration
4	Right femoral hernia anterior to femoral artery, 2cm above the level of right superior pubic ramus.	Lymph Node

Figure 4. Summary of intraoperative findings in patients with non-concordant diagnosis.

40 patients (59%) progressed to an operation. All those who progressed to an operation were repaired via an open approach. Of those operated, 36 patients (90%) had intra-operative findings consistent with ultrasound findings with a positive predictive value of 0.90. In the remaining 4 patients with discordant intra-operative findings, the findings were; no hernia, lymph node, lipoma of cord and right direct inguinal hernia. See Figure 4 for the ultrasound findings as against the intraoperative findings in those with non-concordant diagnosis.

The commonest type of hernia found intraoperatively was indirect inguinal hernia (20) followed by direct inguinal hernia (7) (see Figure 5). Of the 40 patients operated on, 14 were

followed up as described in materials & methods with 64% (n=9) having resolution of symptoms. Haematoma (3) and Pain (2) were the postoperative complications. (See Figure 6).

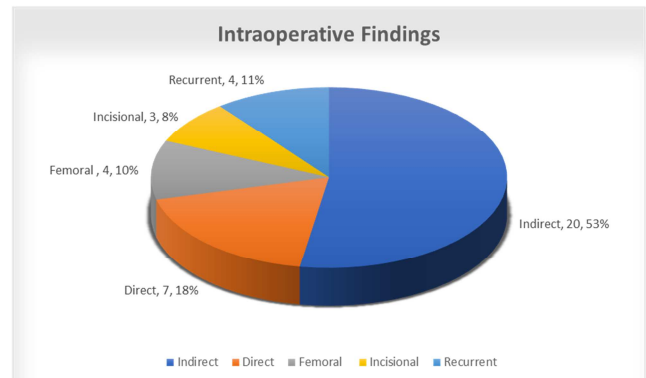


Figure 5. Summary of types of hernia based on intraoperative findings.

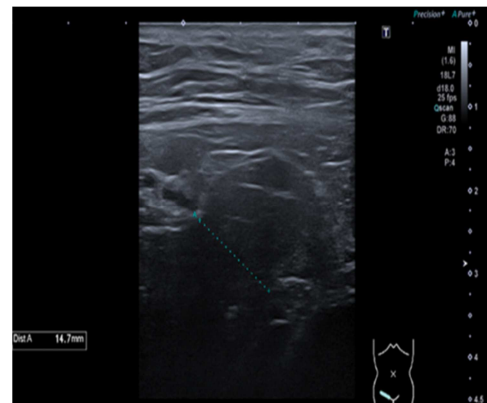


Figure 6. Positive USS groin scan with approximately 15mm defect. Green dotted line measures direct inguinal defect.

4. Discussion

The diagnosis of a hernia is a clinical one. However, this traditional method often missed the smaller occult groin hernias. In a study with 278 patients with clinically diagnosed groin hernias by one surgeon, only 85%, 64% & 39% of these were correctly clinically identified in those with indirect inguinal, direct inguinal & femoral hernias respectively [4]. With the advent of improved imaging techniques and imaging knowledge, we are now using imaging more frequently to aid the clinical diagnosis of hernias especially for the less clinically obvious ‘occult’ hernias. Our study looked to identify the accuracy and usefulness of ultrasound in this group of patients with occult groin hernias.

This study revealed a PPV of 0.90 which is comparable to the study by Alam A. et al who looked at the accuracy of ultrasound in diagnosing occult groin hernias in adults in a prospective study [5]. The total number of patients in that study was 52 patients of which 13 were operated on. This study also correlated the diagnosis of hernia on USS with herniography. High level evidence from a meta-analysis which included 9 original articles, the PPV ranged from 83.3 to 100% with overall PPV of 92.6% [6].

Robinson P. et al in a prospective study describe a PPV of 100% from a total of 18 patients operated on [7]. Similarly, in a prospective study looking at the accuracy of diagnosing hernia types based on the unified classification system, there was a 96% PPV for diagnosing the right type of hernia. However, in a clinically relevant context there was 100% PPV as every hernia detected on USS was confirmed surgically albeit in 5 cases of 125 patients the wrong type was described on USS [8]. This study went on to demonstrate that each type of hernia has a characteristic ultrasonographic imprint. This study had a large sample size.

Lilly MC. et al described USS accuracy for determining any type of hernia at 92%. Total cohort size in this prospective study was 41 patients but 24 of these had bilateral pathology bringing the numbers up to 65 groins. Of note, these USS were performed by surgeons and fellows. In conclusion, they advocated for USS to be performed by surgeons [9].

Depasquale R. et al describe in a retrospective study, a 94% PPV in 62 patients who were operated on [10]. Similarly, Grant T. et al while assessing the use of ultrasonography in women with groin pain describe a 95% PPV from a total of 26 patients who progressed to have surgery [11]. One could argue that including this study with a view to testing the accuracy of USS could be akin to comparing apples and tomatoes. In a study to determine the effectiveness of imaging- USS, computed tomography (CT), and MRI - in the diagnosis of occult inguinal hernia, in nine patients there was a 100% PPV though the author's concluded that the USS cannot reliably exclude occult groin abnormalities [12]. In a prospective study of sonography and herniography for investigation of inguino-femoral pain based on 59 patients (of which 18 patients had surgery), there was a PPV of 100% [13]. Of note, herniography also had a PPV of 100%, however, the sensitivity of sonography was significantly higher than that of herniography (95% vs 70%) & this was statistically significant.

The literature out there on this topic also describes less impressive results which potentially adds credence to the importance on how operator dependence lends itself to interpretation of this imaging modality. A study from Cologne, Germany describes a PPV of 78% while investigating the accuracy of combined physical and colour duplex sonographic examination in the preoperative distinction of direct inguinal hernias. They concluded correspondence of results obtained by physical examination and colour duplex examination leads to high accuracy in the diagnosis of direct inguinal hernias [14]. In a retrospective study based on 375 symptomatic adult patients using operative findings as the gold standard, USS PPV for groin hernias was 70% (95% CI: 62-78%) [15]. This paper concludes by suggesting it may be a useful rule-out test to exclude occult groin hernias in symptomatic patients.

By way of post-operative complications, there were 3 identified cases of haematoma and 2 of pain. Further robust long-term follow-up would be required to assess other complications like recurrence etc. Further studies would be required to assess this. However, in a systematic review based

on 571,445 hernia repairs reported in 39 publications, the most commonly reported complications are bleeding (0.9%), wound infection (0.5%), and pulmonary and cardiovascular complications (0.2%) [16].

We have shown ultrasound is a suitable tool for the initial imaging investigation of occult clinically non-palpable hernia. Our review of current literature has shown wide variance of the choice of imaging technique and the accuracy of their published report. This reflects the reality of imaging difficulty arising from detecting a typical occult hernia which are almost always a small protrusion of fat buried within a 'foreign' area of surrounding fat rather than a protrusion containing other more imaging detectable anatomical structures.

The implication is that detection of small occult fat containing hernia is a difficult imaging challenge and all imaging techniques, including ultrasound, CT, MRI and herniography are operator dependant. Ultrasound imaging has the additional advantage using dynamic process of moving hernia fat within 'foreign' fat in order with visual perception of small subtle hernia. The best imaging result requires a named imaging specialist who is willing to take ownership of hernia imaging and determine the type of hernia imaging protocol with the local surgical team.

Limitations

Evidently, we were unable to determine the negative predictive value as those with negative USS did not progress to groin exploration. Also, sensitivity and specificity could not be ascertained as not every patient who had a positive USS progressed to groin exploration +/- repair. Also, data was not collected, and patients were not followed up after a negative groin ultrasound. We appreciate the fact that a larger sample size would have been more ideal for such a common phenomenon. A multicentre randomized clinical trial would be ideal in validating our findings.

5. Conclusion

Ultrasound is non-invasive and non-ionising radiation imaging modality for diagnosis of impalpable groin hernias with a PPV of 90%. This has been buttressed by high level evidence demonstrating corroboration. Morbidity associated with this modality is low. It is readily available and cheaper thereby conferring a cost benefit as well. With the ever-increasing availability of high-quality cross-sectional imaging such as CT but particularly MRI, we believe that USS still has a place in the diagnostic armamentarium for occult groin hernias in localities lacking ready access to other imaging. Despite this, we acknowledge the drawbacks related to the interpretation of this modality being operator dependant. That being said other high-quality imaging is only as good as the person reporting it's findings as well. We recommend that when thinking of setting up a hernia service it is paramount that a radiologist with a specialist interest is involved in the protocolization, it's day to day running & most importantly performing this USS and reporting in confluence with the local surgical team.

References

- [1] British Hernia Society/ Royal College of Surgeons of England Commissioning guide 2016 on groin hernia.
- [2] NHS Digital. Hospital Episode Statistics (Procedures and Interventions), 2016/17.
- [3] Kingsnorth A, LeBlanc K (2003) Hernias: inguinal and incisional. *Lancet* 362: 1561–1571. <https://doi.org/10.1016/S0140-6736%2803%2914746-0>.
- [4] Moreno-Egea, A., Girela, E., Canteras, M. et al. Accuracy of clinical diagnosis of inguinal and femoral hernia and its usefulness for indicating laparoscopic surgery *Hernia* (2000) 4: 23. <https://doi.org/10.1007/BF01230587>.
- [5] Alam, A., Nice, C. & Uberoi, R. The accuracy of ultrasound in the diagnosis of clinically occult groin hernias in adults *Eur Radiol* 2005 15: 2457. <https://doi.org/10.1007/s00330-005-2825-7>.
- [6] Robinson, A., Light, D. and Nice, C. (2013), Meta-analysis of Sonography in the Diagnosis of Inguinal Hernias. *Journal of Ultrasound in Medicine*, 32: 339-346. doi: 10.7863/jum.2013.32.2.339.
- [7] Philip Robinson, Elizabeth Hensor, Mark J. Lansdown et al Inguinofemoral Hernia: Accuracy of Sonography in Patients with Indeterminate Clinical Features *American Journal of Roentgenology*. 2006; 187: 1168-1178. 10.2214/AJR.05.1251.
- [8] Djuric-Stefanovic A, Saranovic D, Ivanovic A et al The accuracy of ultrasonography in classification of groin hernias according to the criteria of the unified classification system. *Hernia*. 2008 Aug; 12 (4): 395-400. doi: 10.1007/s10029-008-0352-6. Epub 2008 Feb 22.
- [9] Lilly MC, Arregui ME Ultrasound of the inguinal floor for evaluation of hernias *Surg Endosc*. 2002 Apr; 16 (4): 659-62. Epub 2001 Dec 17.
- [10] Depasquale R, Landes C, Doyle G Audit of ultrasound and decision to operate in groin pain of unknown aetiology with ultrasound technique explained. *Clin Radiol*. 2009 Jun; 64 (6): 608-14. doi: 10.1016/j.crad.2008.11.006. Epub 2009 Apr 10.
- [11] Thomas Grant, DO, Erin Neuschler, MD, Wilson Hartz III, MD Groin Pain in Women Use of Sonography to Detect Occult Hernias *J Ultrasound Med* 2011; 30: 1701–1707.
- [12] Miller J, Cho J, Michael MJ et al Role of Imaging in the Diagnosis of Occult Hernias. *JAMA Surg*. 2014; 149 (10): 1077–1080. doi: 10.1001/jamasurg.2014.484.
- [13] Philip Robinson, Elizabeth Hensor, Mark J. Lansdown, N. Simon Ambrose, and Anthony H. Chapman Inguinofemoral Hernia: Accuracy of Sonography in Patients with Indeterminate Clinical Features *American Journal of Roentgenology* 2006 187: 5, 1168-1178.
- [14] Korenkov, M., Paul, A. and Troidl, H. (1999), Color duplex sonography: diagnostic tool in the differentiation of inguinal hernias *Journal of Ultrasound in Medicine*, 18: 565-568. doi: 10.7863/jum.1999.18.8.565.
- [15] E. Alabraba, E. Psarelli, K. Meakin, M. Quinn, M. Leung, M. Hartley, N. Howes The role of ultrasound in the management of patients with occult groin hernias *International Journal of Surgery* Volume 12, Issue 9 2014 Pages 918-922 ISSN 1743-9191 <https://doi.org/10.1016/j.ijssu.2014.07.266>.
- [16] Weyhe, D., Tabriz, N., Sahlmann, B., et al. (2017). Risk factors for perioperative complications in inguinal hernia repair – a systematic review. *Innovative Surgical Sciences*, 2 (2), pp. 47-52. Retrieved 14 Dec. 2019, from doi: 10.1515/iss-2017-0008.