

# Comparison of Management of AVN of Femoral Head by Decompression with TFL Muscle Pedicle Bone Graft and Fibular Graft

Krishna Priya Das<sup>1,\*</sup>, Nakul Kumar Datta<sup>1</sup>, Mohamad Quamruzaman Parvez<sup>2</sup>, Mamunur Rashid<sup>2</sup>, Habibur Rahman<sup>2</sup>, Reza Hassan<sup>3</sup>, Mriganka Bhattacharya<sup>2</sup>, Jahidul H Khan<sup>2</sup>, Zahidul Islam<sup>2</sup>, Rumpa Mani Chowdhury<sup>3</sup>

<sup>1</sup>Department of Orthopaedic Surgery, Bangabandhu Sheikh Mujib Medical University, Shahbagh, Dhaka, Bangladesh

<sup>2</sup>Department of Orthopaedics, Bangabandhu Sheikh Mujib Medical University, Shahbagh, Dhaka, Bangladesh

<sup>3</sup>Department of Neonatology, Bangabandhu Sheikh Mujib Medical University, Shahbagh, Dhaka, Bangladesh

## Email address:

[kdas33@yahoo.com](mailto:kdas33@yahoo.com) (K. P. Das), [kpdas.bsmmu@gmail.com](mailto:kpdas.bsmmu@gmail.com) (K. P. Das)

\*Corresponding author

## To cite this article:

Krishna Priya Das, Nakul Kumar Datta, Mohamad Quamruzaman Parvez, Mamunur Rashid, Habibur Rahman, Reza Hassan, Mriganka Bhattacharya, Jahidul H Khan, Zahidul Islam, Rumpa Mani Chowdhury. Comparison of Management of AVN of Femoral Head by Decompression with TFL Muscle Pedicle Bone Graft and Fibular Graft. *Journal of Surgery*. Vol. 9, No. 1, 2021, pp. 1-9. doi: 10.11648/j.js.20210901.11

Received: November 29, 2020; Accepted: December 10, 2020; Published: January 15, 2021

**Abstract:** Background: Avascular necrosis (AVN) of the femoral head usually occurs in the active age of life, and is an increasingly common cause of musculoskeletal disability. Objective: we envisage to evaluate and compare the clinic oradiological outcomes between TFL muscle pedicle bone graft and no vascularized fibular grafting after core decompression prior to hip joint involvement of AVN femoral head provides painless and mobile life. Method: January 2013 to December 2019, total 64 hips (44 patients) in the age group of 18–48 years (mean 30.36±4.64 years) were included in this prospective study. Ficat and Arlet staging system was used, Stage I (n=10 hips), Stage II (n=44 hips) and stage III (n=10) of AVN of femoral head, were included after clinical and radiological evaluation, where 32 hips (half of all stage-I, II and III) were treated with fibular graft (Group 1) and rest 32 hips were treated with TFL muscle pedicle bone graft (Group 2) after decompression of femoral head. Preoperative Harris Hip Score (HHS), visual analog score (VAS), plain radiographs, and magnetic resonance imaging (MRI) were compared with serial postoperative HHS, VAS, plain radiographs at regular interval. The average follow up was 56 months. Result: Out of 44 patients, male was 28 (63.64%) and female was 16 (36.36%). Failure of surgery was defined as progression of the disease, which was n=1,10% (1/5, 20% in group 1, 0% in group-2) in stage I, n=12/44, 27.27% (7/22, 31.82% in group-1 and 5/22, 22.73% in group-2) in stage II and n=5/10, 50% (2/5, 40% in group 1 and 3/5, 60% in group 2) in stage III disease. Median values of HHS at the end of the follow up in Group I was 80 and 76 in Group 2, compared to the preoperative HHS of 56 and 52 respectively. Overall satisfactory result was 71.88%, p value was <0.01, that is significant. In group 1 satisfactory result was 22/32 (68.75%) but 24/32 (75%) in group 2, no statistical significant difference (>0.05) between two groups. Even in early stage III disease, only 50% was effective. Conclusion: Core decompression with bone graft is effective in preserving the sphericity of the femoral head and to delay the progression in the early stages of the AVN of femoral head, (Stage I and II), fibular graft gives early stability but long term results are similar in both group.

**Keywords:** AVN Femoral Head, Core Decompression, Fibula, TFL Muscle Pedicle Bone Graft

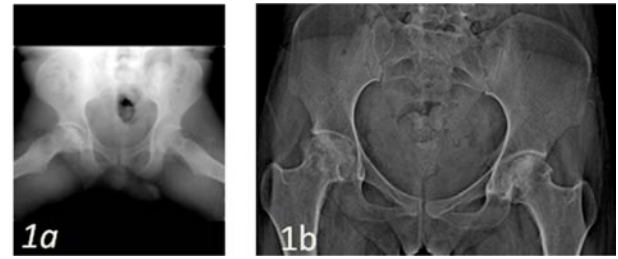
## 1. Introduction

AVN of femoral head is a painful and disabling condition. It

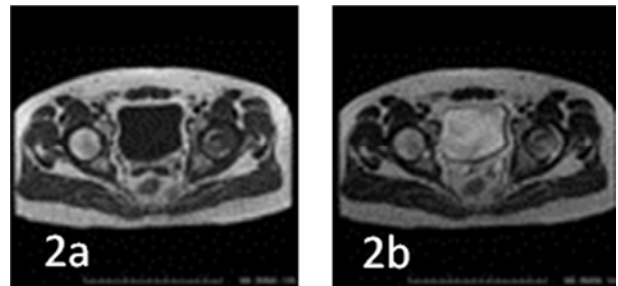
mostly affects the people in third to fifth decade of life [1]. AVN is mostly caused by corticosteroid abuse, but it may also be associated with post traumatic, idiopathic, ITP, ALL, renal, hepatic and skin disorder [2]. Early clinical and radiological

diagnosis is usually difficult but if done in time it may prevent further collapse of femoral head and is important for favorable outcome of disease [3]. The treatment of AVN is done according to staging of the disease. The Ficat's grading system that is based on the plain x-ray, is the most commonly used classification in clinical practice [4]. In the initial stages of disease the head preserving surgeries which aim at reducing intra-osseous pressure and enhancing the vascular supply of the femoral head are preferred. Among these the core decompression of the femoral head is preferred treatment in Ficat stage I and stage IIA diseases [5]. Core decompression (CD) reduces the intra-osseous pressure and thus decreases the pain, but it does not enhance the vascularization of necrosed head adequately, especially in an advanced stage of the disease. Therefore it is better supplemented with various bone grafting or muscle pedicle bone grafting technique to enhance vascularity and healing of the lesion. There are several techniques described to enhance the vascularization of femoral head like CD with vascularised and non-vascularised bone (fibular) grafting, various types of muscle pedicle bone graft etc. Fibular (cortical) graft ensured more structural support but vascularized bone graft enhanced revascularization of necrosed head. Both the procedures have shown favorable results in stage IIA, stage IIB and stage III diseases [6]. Muscle pedicle bone graft has been advanced as a modality of treatment in Ficat et al. stage I & stage II avascular necrosis of the head of femur [7-10]. Untreated osteonecrosis of femoral head ultimately leads to collapse and degeneration of the hip joint. For adequate and proper management of AVN of femoral head, uses a combination of plain radiographs, MRI, Bone scan and clinical features to stage avascular necrosis of the femoral head. In stage 0- plain radiograph: normal, MRI: normal and clinical symptoms: nil. In stage I- plain radiograph: normal or minor osteopenia, MRI: edema, bone scan: increased uptake and clinical symptoms: pain typically in the groin. In stage II-plain radiograph: mixed osteopenia and/or sclerosis and/or subchondral cysts, without any subchondral lucency (crescent sign), MRI: geographic defect, bone scan: increased uptake, clinical symptoms: pain and stiffness. IIA- consider small central lesions, IIB- Multiple small lesion, subchondral crescent sign. In stage III-plain radiograph: crescent sign and eventual cortical collapse, MRI: same as plain radiograph and clinical symptoms: pain and stiffness +/- radiation to knee and limp. In stage IV-plain radiograph: end-stage with evidence of secondary degenerative change, MRI: same as plain radiograph, and clinical symptoms: pain and limp [9-12].

Preservation of femoral head delays the replacement procedures which have finite lifespan. Hence, femoral head-preserving procedures should be considered for the management of properly selected patients in order to delay the arthroplasty. Nevertheless, preservation of head allows for floor level activities which are required for our populations. Therefore, we envisage to analyze the clinical outcome and radiological outcomes after core decompression (CD) and compare between TFL muscle pedicle bone graft with nonvascularized fibular grafting.



**Figure 1.** X-ray Pelvis A/P view. X-ray (1a) showed AVN of femoral head (Rt), stage-III and X-ray (1b), Rt hip-stageIIB and Lt hip-stage IIA.



**Figure 2.** 2a, T1 and 2b, T2 weighted MRI image of AVN of femoral head (Lt), Ficat and Arlet stage-II.

## 2. Methods

This prospective longitudinal observational study was carried out in the department of orthopaedics, BSMMU, from January 2012 to December 2019. Ethical clearance was obtained from the Ethical Committee of the institution. Consecutive sampling technique was used. Adults of age 18–48 years with Stage I, II and early III of Ficat and Arlet classification were included for the study. Early stage III indicates, ROM of hip is good but mild (early) cortical collapse. Hip diseases (AVN) with local site infection, patients with traumatic etiology, psychiatric patients, patients with comorbidities and Ficat-Arlet advanced stage III-IV were excluded from the study. If one hip was in upto early stage III that was included but if another hip involvement was in advanced III or IV excluded that hip but not the patients. The diagnosis of AVN was made based on the clinical and radiological investigations, that is, X-ray and MR. We analysed 48 patients in 64 hips of AVN of femoral head, equally distributed in two groups, Group I considered as non vascular fibular graft group and Group II considered as TFL muscle pedicle bone graft group. Core decompression with removal of maximum necrosed bones from the head in all cases under fluroscope. In group 1, non vascular fibular grafting and in group 2, TFL muscle pedicle bone grafting were done. A detailed history regarding pain and visual analog score (VAS), drug history of steroid intake, smoking and alcohol intake, and history suggestive of coagulation disorders were taken. General examination and systemic examination in detail were done. Local examination of both the hip joints for gait abnormality and restriction of movements were assessed. Blood investigations such as complete blood count and peripheral smear, liver function tests, kidney function tests, random blood sugar, and

coagulation profile were done. X-rays of the pelvis with bilateral hip of anteroposterior view and frog-leg lateral view was obtained. We used Ficat and Arlet classification system for staging. Pre operative MRI was also done in all cases up to stage II disease. Baseline HHS and VAS were recorded. Total 64 hips were equally divided in two groups. Same number 32 and same stages of hips (stage I-5, II-22 & III-5) were included in both group 1 (Fibula) and group 2 (TFL muscle pedicle). CD was done in all cases, after that fibular cortical graft was inserted in group 1 and TFL muscle pedicle grafting in group 2.

## **2.1. Operative Procedure [8-11, 13]**

### **2.1.1. Group 1 (DC with Fibular Grafting)**

The surgeries were done under spinal anesthesia, in supine position on a fracture table and under image intensifier. The lateral femoral cortex was exposed through a short linear incision. Fascia lata and vastuslateralis muscle was divided in line with their fibers and identify the flare of the greater trochanter. A small drill hole was placed in the mid-lateral cortex and entry point was just proximal to the level of lesser trochanter to avoid stress fractures. Small guidewire was inserted through this hole into the center of the lesion in the femoral head. With the help of the triple reamer (8 mm) of dynamic hip screw, which was slowly advanced into the lesion and necrosed bone was removed and sample was sent for biopsy. Autograft of fibula about 8-10 cm was obtained, proximal end made tapered and distal end was made rounded. The appropriate length of the graft was measured from the reverse measuring device. Graft was passed through the lateral cortex to place up into the head with the proximal end just underneath the subchondral bone within 5 mm from the outer cortex, in the area of the lesion. In addition cancellous bone graft was put if there was large lesion. Closure was done in layers.

### **2.1.2. Group 2 (DC with TFL Muscle Pedicle Bone Graft)**

The patient was positioned supine and small sand bag behind the buttock at the affected side and incision was made as described by smith-peterson anterior approach [13]. The groove between the sartorius and tensor fascia lata muscle and the deep fascia overlying the TFL was identified. An incision was then made along the direction of muscle fibre of TFL, 2.5 cm behind the anterior edge of the muscle. The isolated anterior fibre of TFL was elevated and its deeper fibres found intermingled with those of the underlying gluteus-minimus were sectioned. A titanium made 4mm diameter X 45mm cancellous lag was inserted, then centering this screw a cone shape segment of iliac crest 2.0 cm X 1.5cm and 2.0 depth was osteotomised, 1.5 cm behind the ASIS and retracted down keeping its attachment to the anterior fiber of TFL. The muscle pedicle bone graft was prepared, gets its blood supply from the superior gluteal artery and ascending branch of lateral circumflex femoral artery. Bleeding from the raw surface of the muscle pedicle bone graft was observed. Next the anterior capsule of the hip was opened, using an inverted T incision. Multiple drill holes

were made over the anterior surface at head neck junction, 2 cm medial to the lateral cortex, and a small window 1.5X1.5 cm was made to accommodate TFL muscle bone graft without tension and through curettage was done and removed all the necrosed bone of the head especially weight bearing zone of the head. Free cancellous bone graft was harvested from iliac crest and packed the deeper part of the cavity of diseased head. Then the bony portion of muscle pedicle bone graft was shaved according to contour of the slot, one drill hole was made centering the window and perforate the posterior cortex, 1cm lateral to the medial cortex. The muscle pedicle bone graft is impacted inside the cortical window and fixed with one 4mm screw and finally anchored the overlying fascial sleeve to the surrounding capsule and soft tissue. The cut margin of the capsule and gluteus minimus muscle were then repaired to secure the graft. The wound was closed in layers over the suction drain.

## **2.2. Post Operative Follow up**

Check X-ray was obtained on postoperative day 1 and VAS was recorded. In postoperative period, absolute nonweight bearing regimen was followed with traction of 2 kg throughout the day for first 1 week and during night times for next 2 weeks. Active assisted range of motion exercises were started after 1 week and passive range of exercise was started on the 2<sup>nd</sup> weeks on ward. Patient was discharged after 5 days. Partial weight bearing was allowed after 6 weeks and full weight bearing was permitted after 12 weeks. Clinico-radiological follow-up was done at 1 week, 2 weeks, 4 weeks, 12 weeks, 6th month, and subsequently every 6 months. One week after discharge, patient was evaluated for surgical site infection and VAS score was recorded. Serial X-rays were obtained at the interval of 2 weeks, 4 weeks, 12 weeks and 6 months and at every 6 monthly, which was compared with the preoperative plain radiographs and MRI for signs of revascularization and preservation of sphericity of the femoral head. Functional outcome was assessed with the comparison of the serial VAS scores and Harris Hip Scores (HSSs). The average follow up was 56 months (range 12–120 months).

## **2.3. Outcome Was Evaluated with Post Operative X-ray, VAS and Subjective Harris Hip Score [12]**

Outcome, Score and patients satisfaction was graded by following:

Excellent: Hip score: 91-100 (patient was very satisfied).

Good: Hip score: 81-90 (patient was satisfied).

Fair: Hip score 71-80 (patient was satisfied but not up to the mark).

Poor o: Hip score < 70 (patient was not satisfied).

Radiological criteria of improvement [7, 9, 10].

1. The diminution of density of necrotic portion of femoral head.

2. Return to normal density of pre-operative rarefied areas, restoration of normal trabecular pattern.

3. Disappearance of the crescent sign

#### 4. Healing of the cystic areas and of the fracture line.

#### 2.4. Statistical Analysis

The information collected on the questionnaires were entered into Microsoft Excel and after data cleaning, the data were transferred and further analyzed using SPSS software version 22. These outcome variables were found to be skewed, hence median values were considered and statistical analysis was done using nonparametric test. The preoperative HSSs and VAS scores were compared with that of HSSs and VAS scores at serial intervals of follow up and final follow up at least 6 months after operation. Statistical analysis was carried out by unpaired students t-test, Chi-square test and Z-test. Level of significance was considered significant when P-value was 0.05 or less.

### 3. Results

A total of 64 hips (n=44 patients) were identified as being eligible for the study. The average age of the patients was  $30.36 \pm 4.64$  years (range 18–48 years). 28 (63.64%) males with 42 hips (65.63%) and 16 (36.36%) female patients with 22 hips (34.38%) were included in the study and the sex ratio being 1.75. Out of 44 patients, unilateral hip involved patient was 24 (54.55%) and bilateral hip involved patients were 20 (45.45%), but out of which 10 patients (50%) presented with symptoms pertaining to only one hip, the other hip was in stage I. On the other hand, out of 64 hips, 36 hips had involvement of the right side (56.25%), and left hip involvement was 28 (43.75%). 24 patients (54.54%) had unilateral involvement in study group, but including all hip AVN (all stage III and IV), bilateral involvement was 80% of cases. Out of 64 nontraumatic AVN of femoral head, cortico steroid induced was 48 (75%) hips, idiopathic was 12 (18.75%), ITP related was 2 (3.13%), and alcohol induced was 2 (3.13%). According to Ficat and Aret's staging, out of 64 hips, stage-I was 10 (15.63%), all cases were detected by screening MRI, other hip was stage II or III, stage-II was 44 (68.75%), and early stage III was 10 (15.63%) hips. Average duration of surgery was 90 (range 70-120) minutes in group 1 and 70 (range 50-90) minutes in group 2. Average duration of follow up was 56 (range 12 to 120) months. Clinical evaluation was done by modified Harris hip score and VAS. Excellent outcome was 17 (26.56%)

hips, good was 21 (32.81%) hips, fair was 8 (12.50%) hips and poor was 18 (28.13%) hips. Excellent, good and fair results were grouped as satisfactory, on the other hand poor result was grouped as unsatisfactory. Overall Satisfactory outcome was 46/64 (71.88%) and unsatisfactory outcome was 18 (28.12%) hips. Radiological progression was not seen in 46 out of 64 hips (71.88%), whereas 18 hips (28.12%) were demonstrated signs of progression and collapse, that was 10 (31.25%) in group-1 and 8 (25%) in group-2. Failure of surgery was defined as progression of the disease, which was n=1/10, 10% (1/5, 20% in group 1, 0% in group-2) in stage- I, n=12/44, 27.27% (7/22, 31.82% in group-1 and 5/22, 22.73% in group-2) of stage II and n=5/10, 50% (2/5, 40% in group 1 and 3/5, 60% in group 2) of stage III disease. Median values of HHS at the end of the follow up in Group I was 80 and 76 in Group 2, compared to the preoperative HHS of 56 and 52 respectively. Median values of VAS at the end of the follow up was 2.82, compared with preoperative 5.85. In stage I, preoperative mean VAS was 2, compared with 1 at 6 month follow up, in stage II disease, preoperative mean VAS was 6, compared with postoperatively, it reduce to 2.75 at 6 months but in stage III disease, preoperative score was 9 and post operative score was 5. Overall satisfactory result was 71.88%, p value was <0.001 by Z test, that is significant. In group 1 satisfactory result was 22/32 (68.75%) and 24/32 (75%) in group 2, no statistic significant difference (>0.05) between two groups. In group 1, 80%, 68.18% and 60% of stage I, II and III respectively were satisfactory results but in group 2, 100%, 77.27% and 40% were satisfactory results. The correlation between the Ficat's stages, Harris Hip score and VAS have shown that majority of hips were showing excellent and good score belonged to stage I and II, 36/54 (66.67%) but no excellent result in stage III disease in both groups, only 20% was good result in stage III. 5/10 (50%) of hip was poor result in stage III AVN, 2/5 (40%) in group 1 and 3/6 (60%) in group 2. The scores difference between pre and postoperatively in stage I and II were also statistically significant but comparison between two groups was not significant, on the other hand in stage III disease, difference between pre and post operative results were not significant and inter-group difference also not significant.

**Table 1.** Age and sex distribution of patients.

Age group	Male (%)	Female (%)	No of patients (%)	No of hip involved (%)
18- 30 years	09 (20.45%)	05 (11.36%)	14 (31.82%)	20 (31.25%)
31-40 years	13 (29.17%)	07 (16.67%)	20 (45.45%)	30 (46.88%)
41-48 years	06 (13.64%)	04 (09.09%)	10 (22.73%)	14 (21.85%)
	28 (63.64%)	16 (36.36%)	44 (100%)	64 (100%)

Mean age of the patient was  $30.36 \pm 4.64$  years (range 18–48 years). 28 (63.64%) was males with 16 (36.36%) was female. Male, female ratio being 1.75.

**Table 2.** Side of involvement.

Side of hip involvement	Number of hips (%)	Percentage
Unilateral involve patient	24	54.55%
Bilateral involve patient	20	45.45%
Right hip involvement	36	(56.25%)
Left hip involvement	28	(43.75%)
Total	64	100%

Unilateral hip involvement was 24 (54.55%) and bilateral hip involved patients were 20 (45.45%), On the other hand, out of 64 hips, 36 hips had involvement of the right side (56.25%), and left hip involvement was 28 (43.75%).

**Table 3.** Aetiology of AVN of femoral head.

Mode of diseases	Number of hip involved	Percentage
i) Corticosteroid induced	48	75%
a) Connective tissue disorder - 22/48 (45.83%)		
b) CKD - 12/48 (25.00%)		
c) Respiratory diseases -11/48 (22.92%)		
d) Dermatomyositis -01/48 (02.08%)		
e) ALL -02/48 (04.17%)		
ii) Idiopathic	12	18.75%
iii) ITP	02	03.13%
vi) Alcohol induced	02	03.13%
	64	100%

According to cause, cortico steroid induced was 48 (75%) hips, idiopathic was 12 (18.75%), ITP related was 2 (3.13%), and alcohol induced was 2 (3.13%).

**Table 4.** Stages of AVN of Femoral Head.

Ficat and Arlet stage	Number of patient	Group 1 No of hip involved (%)	Group 2 No of hip involved (%)
I	All are in B/L cases	5 (15.62%)	5 (15.62%)
II	34	22 (68.75%)	22 (68.75%)
III	10	05 (15.63%)	05 (15.63%)
	44	32 (100%)	32 (100%)

According to Ficat and Aret's staging, out of 64 hips, stage-I was 10 (15.63%), all cases were detected by screening MRI, other hip was stage II or III, stage-II was 44 (68.75%), and early stage III was 10 (15.63%) hips.

**Table 5.** Evaluation of results according to Harris Hip Score.

Ficat-Arlet stage	Group	No of hips (%)	Results/ According to HHS			
			Excellent (90-100)	Good (80-89)	Fair (70-79)	Poor (<70)
I	Group 1	5 (15.62%)	3 (60%)	1 (20%)	0	1 (20%)
	Group 2	5 (15.62%)	3 (60%)	2 (40%)	0	0
II	Group 1	22 (68.75%)	6 (27.27%)	7 (31.82%)	2 (9.09%)	7 (31.82%)
	Group 2	22 (68.75%)	5 (22.73%)	8 (36.26%)	4 (13.64%)	5 (22.73%)
III	Group 1	5 (15.62%)	0	2 (40%)	1 (20%)	2 (40%)
	Group 2	5 (15.62%)	0	1	1 (20%)	3 (60%)
		64 (100%)	17 (26.56%)	21 (32.81%)	8 (12.50%)	18 (28.13%)

Excellent outcome was 17 (26.56%) hips, good was 21 (32.81%) hips, fair was 8 (12.50%) hips and poor was 18 (28.13%) hips. Excellent, good and fair results were grouped as satisfactory, on the other hand poor result was grouped as unsatisfactory. Overall Satisfactory outcome was 46/64 (71.88%) and unsatisfactory outcome was 18 (28.12%) hips, out of 18, 10 (31.25%) in group-I and 8, (25%) in group-II.

**Table 6.** Correlation of result between age with the Harris Hip Score

Age group	No of hips Involved (%)	Results			
		Excellent	Good	Fair	Poor
18- 30 years	20 (31.25%)	8 (40%)	5 (25%)	3 (15%)	4 (20%)
31-40 years	30 (46.88%)	7 (23.33%)	12 (40%)	3 (10%)	8 (26.67%)
41-48 years	14 (21.85%)	2 (14.29%)	4 (28.57%)	2 (14.28%)	6 (42.86%)
	64 (100%)	17 (26.56%)	21 (32.81%)	8 (25%)	18 (28.13%)

In age group of below 30 years, excellent, good and fair results were 80%, in 31-40 years it was 73.33% but only 57.87% in age group of above 40 years.

**Table 7.** Correlation of Ficat's stage with the Harris Hip Score and VAS.

Ficat-Arlet stage		Harris hip score		Visual analogue scale		P value
		Pre-operative (mean)	Post-operative (mean)	Pre-operative (mean)	Post-operative (mean)	
I	Group-1	78	93	2	1.2	HHS, p <0.005 VAS, p <0.05
	Group-2	76	94	2	1	
II	Group-1	60	77	6	2.60	
	Group-2	59	79	6.2	2.55	
III	Group-1	42	66	8	4.5	
	Group-2	40	62	8.5	5.5	
Total		59.34	78.23	5.80	2.72	

In stage I AVN, pre operative mean HHS was 77 and post operative mean 93.5, on the other hand VAS was 2 and 1.1 respectively, but in stage II disease, preoperative mean HHS was 59.5 and postoperative score was 78. On the other hand VAS was 6.1 and 2.58 respectively. In stage III AVN, preoperative mean HHS and VAS was 41 and 8.25 consecutively, and postoperative score was 64 and 5 respectively. Overall, median values of HHS at the end of the follow up was 78.23, in compare with preoperative score was 59.34 and VAS score was 2.72, compare with 5.80 successively.

**Table 8.** Final outcome.

Ficat-Arlet stage	Group	Total hip involved	Outcome (HHS+VAS)		Final outcome	
			Excellent, Good, Fair	Poor	Satisfactory	Unsatisfactory
I	Group 1	5	4 (80%)	1 (20%)	9 (90%)	1 (10%)
	Group 2	5	5 (100%)	0		
II	Group 1	22	15 (68.18%)	7 (31.82%)	32 (72.73%)	12 (27.27%)
	Group 2	22	17 (77.27%)	5 (22.73%)		
III	Group 1	5	3 (60%)	2 (40%)	5 (50%)	5 (50%)
	Group 2	5	2 (40%)	3 (60%)		
Total		64 (100%)	46 (71.87%)	18 (28.13%)	46 (71.87%)	18 (28.13%)

P value between preoperative and postoperative by Z test, is <0.001 that is significant.

P value between group 1 and 2, by Z test, is >0.05 that is not significant.

P value between preoperative and postoperative in Ficat-Arlet stage I and II, by Z test, is <0.05 that is significant, but in stage III is not significant, >0.05.

## 4. Discussion

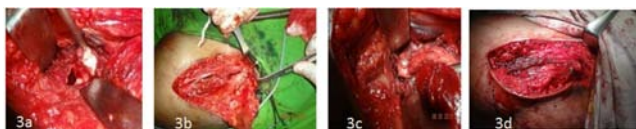
AVN of femoral head is a major musculo-skeletal problem [12, 14]. If it is left untreated it may progress to secondary osteoarthritis of hip joints. The natural progression of the disease is inevitable. Therefore early diagnosis & treatment of AVN may result in favorable outcome of the disease. Medical management of AVN is usually not satisfactory, although some studies have shown the efficacy of bisphosphonate in the early AVN with small necrotic lesion [15]. The advanced stage of AVN is only satisfactory option remains is total hip arthroplasty [16]. The etiology of AVN has been to be multifactorial and may be associated with various risk factors. Those without any obvious risk factor are considered as idiopathic AVN of femoral head [17]. Alcoholism (consuming up to 400ml per week) has been reported as a major risk factor for AVN of femoral head. Exposure to alcohol consumption and corticosteroid account for 90% of all cases of AVN has been reported [18, 19]. The classification or staging system of AVN of femoral head is important to plan its treatment. The most commonly used classification in clinical practice is Ficat's classification system. We have used Ficat's classification since it is simple, easy to use and has good reproducibility. It grades the disease process into four stages [11, 20]. The aim of treatment in early stages of AVN of femoral head is to perform the head preserving procedure by reducing the intraosseous pressure and enhancing the vascular supply of femoral head. Only

core-decompression of femoral head was reported with a promising result, initially by Hungerford [21]. The effectiveness of core decompression has always been a controversy in the literature. The long term results have shown that only core decompression gives only temporary relief of pain but does not prevent the progression of the collapse of femoral head. Buckley et al. have reported good outcomes with the use of cortico-cancellous bone graft along with core decompression in Ficat's stage I & IIA of AVN of femoral head [22]. The permeation of granulation tissues into the drilled area growing from the adjacent MPBG helps in revascularization of the necrotic area, resulting in long lasting pain relief [9, 11]. Various free vascularised grafts for treatment of AVN of femoral head to achieve adequate vascularization in the necrosed femoral head, Urbanik et al [23] have used fibula (with peroneal vascular pedicle). They have shown good clinical & radiological outcome with free vascularised bone graft in Ficat stages IIB and III also. However these procedure are technically demanding, tedious and time consuming and not feasible bilaterally in one sitting [23, 24]. To overcome the shortcomings of vascularised grafts, various types of muscle pedicle bone grafting procedure (after core decompression) have been described. These procedures have shown favorable outcome in early stage of the disease with revascularization of the femoral head and prevention of collapse. They described muscle pedicle graft technique include Meyer's procedure using, quadratus femoris muscle pedicle graft [25], Baksi's procedure used tensor fascia lata graft along with iliac crest



bone graft [9] and Sartorius muscle pedicle graft by Lie et al. [26] after decompression of necrosed femoral head with multiple drill holes. The shortcoming of graft slippage has been reported. Tensor fascia lata muscle pedicle bone graft is seen to be more vascular than Sartorius graft. The study allowed sufficient decompression by adequate removal of necrotic subchondral bone of the head of the femur at weight bearing area and fixation of graft with one 4mmX40-50mm cancellous lag screw, this prevent slippage of the graft from neck window [9, 27]. In this study, pre-collapse stage of osteonecrosis and early collapse with good range of hip movement cases, TFL muscle-pedicle bone graft being cortico-cancellous provided a better strut effect to the sub chondral area and prevented their collapse more efficiently than those obtained by quadratus femoris [25], Sartorius [26] or gluteus medius MPBG having mostly spongy bones [9]. On the other group cortical fibular graft was provided strong support to the disease subchondral bone [8]. The newer technique describing the use of autogenous stem cells from iliac crest and platelet rich plasma for the necrosed area of the femoral head have shown very good result in early stage-I & IIA of the disease but results in advanced stage of disease are unsatisfactory. In our comparative study shown, 80% of Ficat stage I, 68.18% of stage II and 60% of stage III was satisfactory result in core decompression with fibular graft group, on the other hand 100% of Ficat stage I, 77.27% of stage II and 40% of stage III shown satisfactory result in core decompression and TFLM graft group. Both the groups are almost similar results but fibular cortical graft was relatively given more structural support and prevent collapse but operative time and complications were more in fibular graft group. Overall, satisfactory results shown in Ficat and Arlet stage I & II in core decompression and bone graft, either with fibula or muscle pedicle bone graft but even in early stage III, unsatisfactory results was almost 50%. Although THA has been shown to give excellent results in late stage of AVN (advanced-III and IV), but due to the limited life span of these prosthesis become a great problem in younger patient.

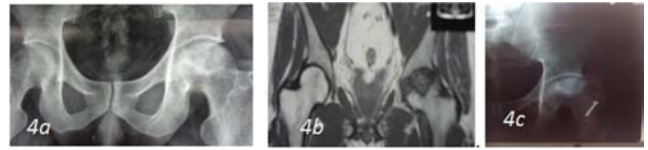
## 5. Conclusion



**Figure 3.** 3a- Anterior approach of the hip (smith-petersen), 3b-Predrilled and pre fixed 4mm cancellous lag screw before osteotomy of iliac crest, and 3c, 3d- Fixed the TFL muscle pedicle bone graft through anterior neck window at head-neck junction area.

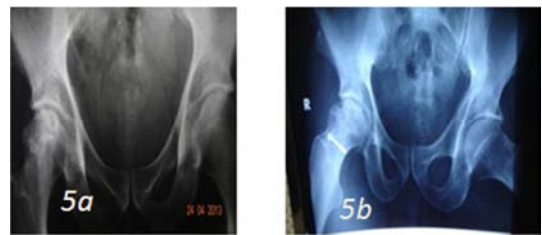
Core decompression and TFL muscle pedicle bone grafting or non vascular fibular graft reduced intra osseous tension and to achieve early revascularization of the ischaemic femoral head that relieved hip pain, improve hip function, also prevent collapse of femoral head and able to achieve satisfactory outcome. Both the procedures have almost the equal result.

Case illustration-1 (Core decompression with MPBG) operative procedure.



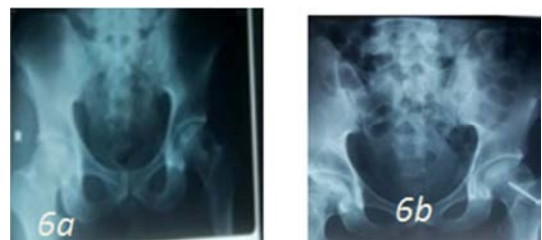
**Figure 4.** 4a, Preoperative X-ray pelvis AP view & 4b MRI Hip joints showing Ficat stage IIB of AVN in left femoral head. 4c- Postoperative X-ray at 15 month (core decompression & Tensor fascia lata muscle pedicle bone graft with screw) showing gradual healing of necrotic area.

Case illustration-2(Core decompression with MPBG)



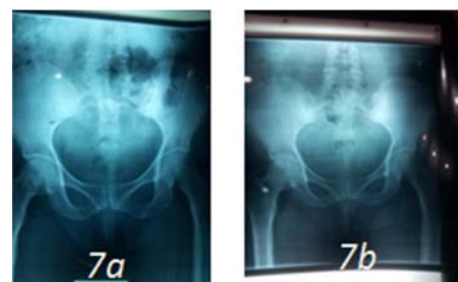
**Figure 5.** 5a, 50yrs old male, pre operative AVN right femoral head stage III. 5b- 2 years follow up of same patient showing satisfactory healing of necrotic area with improvement of shape of femoral head.

Case illustration-3(Core decompression with MPBG).



**Figure 6.** 6a, 32yrs male, preoperative alcohol induced AVN stage IIB femoral head. 6b, postoperative x-ray at 3 years follow up showing gradual healing of necrotic area with improvement shape of femoral head.

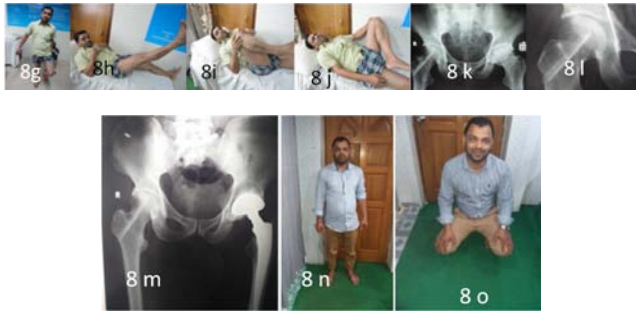Case illustration-4(Core decompression with MPBG).



**Figure 7.** 7a, Pre operative X-ray of 41 yrs female, CKD (steroid induced AVN of both femoral head, Stage IIA at right side. 7b: Postoperative follow up X-ray at 6 month, gradual healing at right side.

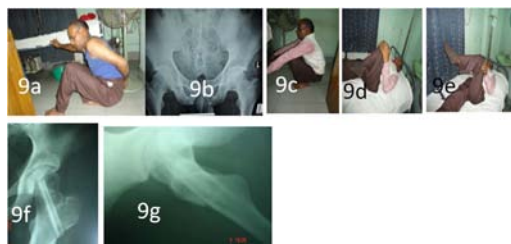Case illustration-5 (Core decompression with fibular graft).





**Figure 8.** 8a-b, Preoperative X-ray & MRI, shown- AVN femoral head, Ficat stage-II (Rt) & III (Lt), 8 c-f, shown per-operative (Rt hip) photo, 8 g-l, follow up at 6 months, Rthip, good improvement with decompression and fibular graft but Lt hip, deteriorate progress in stage Ficat stage-IV, 8 m-o, follow up at 7 years after initial operation of right hip.

Case illustration-6(Core decompression with fibular graft).



**Figure 9.** a-b, Shown pre-operative X-ray, AVN femoral head (Lt), Ficat-Arlet stage-II/ early III, 9c-g post operative clinical findings & Xray at 9 months, good range of motion and improved femoral head circulation and maintained contour.

## Ethical Issue

This topic was presented several times in Bangladesh Orthopaedic Society annual Conference, and also study as a MS thesis article in BSMMU, Dhaka, Bangladesh. IRB No. BSMMU/2013/6302. The topic was “Muscle pedicle bone graft versus non vascular fibular graft for the management of AVN of femoral head at pre-collapse stage”.

## Conflict of Interest

There is no potential conflict of interest with respect to the research, authorship, and /or publication of this article.

## Acknowledgements

We owe our heartfelt gratitude and indebtedness to all of our patients those who are participate in this study and specially thanks to Prof Dr. Anwarul Islam Chowdhury, Ex-Chairman, Prof Dr. Nakul Kumar Datta, and Prof Dr. Abu Zafor Chowdhury, Chairman, department of Orthopaedics, BSMMU.

## References

- [1] Herndon JH, Aufranc OE, A vascular necrosis of the femoral head in the Adult. A review of its incidence in a variety of conditions. Clin Orthop 1972; 86: 43-62.
- [2] Glimcher MJ, Kenzora JE. The biology of osteonecrosis of the human femoral head and its Clinical implications: part III. Discussion of the etiology and genesis of the, pathological sequelae; Comments on treatment Clin Orthop 1979; 140: 273-312.
- [3] Tripathy SK, Goyal T, Sen RK et al. Management of femoral head osteonecrosis: current concepts. Indian J orthop 2015; 49: 28-45.
- [4] Jawad MU, Haleem A, Scully SP. Ficat classification: Avascular Necrosis of the femoral head. ClinOrthopRelat Res 2012; 470: 2636-9.
- [5] Fairbank AC, Bhatia D, Jinnah RH. et al. Long –term results of core decompression for Ischaemic necrosis of the femoral head. J Bone Joint Surg Br 1994; 76-B: 42-9.
- [6] Mont MA, Hungerford d DS. Non traumatic avascular necrosis of femoral head. J Bone Joint Surg Am 1995; 77A: 459-74.
- [7] Ficat RP. Idiopathic bone necrosis of the femoral head, early diagnosis, and treatment. J Bone Joint Surg Br 1985; 67B; 3-9.
- [8] Lakshminarayana S, Dhammi IK et al. Outcomes of Core Decompression with or without Nonvascularized Fibular Grafting in Avascular Necrosis of Femoral Head: Short Term Follow up study. Indian J Orthop. 2019 May-Jun; 53 (3): 420–425.
- [9] Bakshi DP. Treatment of AVN of the Femoral head by drilling and muscle pedicle bone grafting. J Bone Joint Surg Br 1991; 73 (2): 241-245.
- [10] Canale ST, Beaty j H. Management of osteonecrosis of head of femur. Campbell's operative orthopaedics 11<sup>th</sup> ed. Philadelphia, USA: Elsevier; 2007.
- [11] Rosenwasser MP, Garino JP, Kiernan et al. Long term follow up of through debridement and cancellous bone grafting of the femoral head for avascular necrosis. ClinOrthopRelat Res 1994; 306: 17-27.
- [12] Harris WH. Traumatic arthritis of the hip after dislocation and acetabular fracture. Treatment by mold arthroplasty. An end result study using a new method of result evaluation. J Bone Joint Surg Am 1969; 51; 737-55.
- [13] Smith-petersen MN. Approach to and exposure of the hip joint for mold arthroplasty J Bone Joint Surg Am 1949; 31A: 40-6.
- [14] Zalavras CG, Liberman JR, osteonecrosis of the femoral head: evaluation and treatment. J Am AcadorthopSurg 2014; 22: 455-64.
- [15] Luo RB, Lin T Zhong HM et al. Evidence for using alendronate to treat adult avascular necrosis of the femoral head: a systematic review. MedSciMonit 2014; 20:2439-47.
- [16] IssaK, Pivec R Kapadia BH et al. osteonecrosis of the femoral head: the total hip replacement solution. Bone Joint J 2013; 95-B: 46-50.
- [17] Patterson RJ, Bickel WH dahl D Cet al. Idiopathic avascular necrosis of the head of the femur. J Bone Joint Surg Am 1964; 46: 267- 82.
- [18] Matsuo k, Hirokawa T Sugioka Y et al. Influence of alcohol intake, cigarette smoking and occupational status on idiopathic osteonecrosis of the femoral head. Clin. orthop 1988; 234: 115-23.



- [19] Cruess RL. Steroid- induced osteonecrosis: a review. *Can J Surg* 1981; 24: 67-71.
- [20] Shah SN, Kapoor CS, Jhaveri MR, Golwala PP, Patel S. Analysis of outcome of avascular necrosis of femoral head treated by core decompression and bone grafting. *J ClinOrthop Trauma*. 2015; 6: 160–6. [PMC free article] [PubMed] [Google Scholar].
- [21] Hungerford DS. Response: the role of core decompression in the treatment of ischemic necrosis of the femoral head. *Arthritis Rheum* 1989; 32: 801-6.
- [22] Buckley PD, Gearen PF, Petty RW. Structural bone-grafting for earlyatraumaticavacular necrosis of the femoral head. *J Bone joint Surg Am* 1991; 73: 1357-64.
- [23] Urbaniak JR, coogan PG Gunneson EB et al. treatment of osteonecrosis of the femoral head with free vascularized fibular graft-ing. A longter follow up study of one hundred and three hips. *J bone Joint Surg Am*1995; 77: 681-94.
- [24] Babhulkar S. osteonecrosis femoral head treatment by core decompression and iliac crest TFL muscle pedicle grafting. In: Zoria A, editors. *Bone grafting*. 1<sup>st</sup> edn. Croatia: In Tech; 202. p. 108-124.
- [25] Meyers MH. The treatment of osteonecrosis of the hip with fresh osteochondral allografts and with the muscle pedicle graft technique. *CliniOrthop* 1978; 130: 202-9.
- [26] Zhou L, Tan J, Li Y. Treatment avascular necrosis of femoral head in young adult by grafting Sartorius muscle iliac graft bone flap. *Zhongguo Xiu Fu Chong Jian Wai Ke Za Zhi* 2007; 21: 814-16.
- [27] Hernigou P, Beaujean F. Treatment of osteonecrosis with autologus bone marrow grafting. *Clin Ortho Relat Res* 2002; 405: 14-23.