

# COVID-19 Associated Spontaneous Bowel Perforation

Mohammed Alkatary<sup>1, 2, \*</sup>, Hamda Al Zarooni<sup>1</sup>, Salem Al Harthi<sup>1</sup>

<sup>1</sup>General Surgery Department, Sheikh Shakhboub Medical City (SSMC), Abu Dhabi, UAE

<sup>2</sup>General Surgery Department, Mansoura University, Mansoura, Egypt

## Email address:

mohammedkatary1@yahoo.com (M. Alkatary)

\*Corresponding author

## To cite this article:

Mohammed Alkatary, Hamda Al Zarooni, Salem Al Harthi. COVID-19 Associated Spontaneous Bowel Perforation. *Journal of Surgery*. Vol. 9, No. 2, 2021, pp. 74-77. doi: 10.11648/j.js.20210902.16

**Received:** March 7, 2021; **Accepted:** March 19, 2021; **Published:** March 30, 2021

---

**Abstract:** The purpose of this article is to report on the newly recognized life threatening gastrointestinal complications of Corona virus infection (COVID-19) in the form of bowel ischemia and ischemic bowel perforation. In a retrospective observational study at Sheikh Shakhboub Medical City (SSMC), Abu Dhabi, United Arab Emirates during the period between March and May 2020. All COVID-19 positive patients with free intra peritoneal air were included; total of five patients met our inclusion criteria during the study period, all patients were admitted to the intensive care unit for mechanical ventilation and management of severe COVID 19 related respiratory complications. COVID-19 status was based on a positive PCR nasopharyngeal swab supported by typical radiological findings on either chest X-ray (CXR) or CT Chest. Free air under the diaphragm was radiologically confirmed in all patients. Patients' demographics and co-morbidities were reviewed. Four patients underwent an emergency surgical intervention confirming ischemic perforation of the right colon. The caecum was identified as the starting point of ischemia with variable distal extension into the ascending colon and the hepatic flexure. One patient unfortunately demised prior to surgery due to severe septic complications. These findings highlight the importance of paying attention to COVID 19 patients with sudden clinical deterioration and raise the extent of the gastrointestinal manifestation of COVID-19 infection beyond simple diarrhea and abdominal pain.

**Keywords:** Colonic Perforation, COVID-19, Hemicolectomy

---

## 1. Introduction

Coronavirus are named for the crown-like spikes on their surface. The main subgroups of coronaviruses are alpha, beta, gamma and delta. [1] Previously identified coronaviruses, SARS-CoV and MERS-CoV belongs to the beta subgroup of the coronavirus family. The novel COVID 19, also known as SARS-CoV-2 belongs to the beta subgroup of the coronavirus as well. [2]

In December 2019, the world health organization declared SARS-CoV-2 pneumonia as a public health emergency of global concern. SARS-CoV-2 which is also known as coronavirus 2019 (COVID 19). [3]

Initially developed in one of the largest Chinese cities, Wuhan. Around 60% of patients affected by COVID-19 are male with a median age of 50 years. 5% of patients requiring admission to intensive care unit. [4, 5]

The initial apparent symptoms that was described in

almost all literatures were fever, cough and respiratory distress which affected 40% of patients. [6, 7]

Other disease related complications also came to light, including thromboembolism, disseminated intravascular coagulopathy, and kidney and liver injuries. [8]

Few weeks down the line more unusual symptoms started to stigma these patients like diarrhea, abdominal pain, anorexia and vomiting. [9]

More serious gastrointestinal complications including colonic perforations were recently reported in the literatures as single case reports.

## 2. Methods

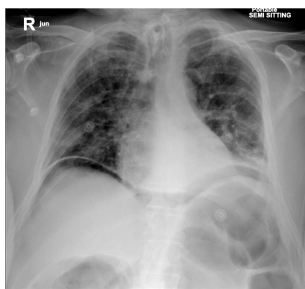
This is a retrospective observational study of patients admitted to SSMC between March and May 2020 with COVID-19 pneumonia, complicated by radiologically proven bowel perforation during the same admission. A total of five

male patients fitting the inclusion criteria were identified, mean age at presentation 51 years, ranged between 30 and 66 years.

They were admitted to our institute with respiratory symptoms including cough, shortness of breath and fever; symptoms on average started 5 days prior to hospital admission.

They were all confirmed Positive for SARS-CoV-2 on a Respiratory Tract – Polymerase Chain Reaction (RT-PCR) using a nasopharyngeal swab, all had typical radiological findings on chest imaging supportive for the diagnosis.

All patients were treated for COVID-19 as per the established hospital protocol at the time. Four patients had considerable comorbidities (two were diabetics, one diabetic with ischemic heart disease; one had end stage renal failure on dialysis, ischemic heart disease and hypertension). All five patients were admitted to the intensive care unit, intubated and mechanically ventilated for respiratory failure. Sudden unexpected deterioration in their clinical condition associated with some degree of abdominal distension and raised inflammatory markers raising the suspicion of an intra-abdominal pathology. Free intra-abdominal air was demonstrated in all patients, on semi sitting chest X-ray in three patients and on CT scan of the abdomen in two patients.



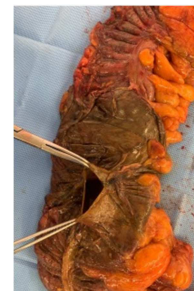**Figure 1.** Chest X ray. (Bilateral air under diaphragm with covid pneumonia).

One patient demised prior to surgical intervention due to severe septic shock, CT scan showed poor enhancement of both kidneys, right colon and pneumatosis of a short segment of distal ileum causing perforation most likely due to global ischemia.

Four patients underwent emergency damage control laparotomy, right hemi-colectomy or extended right hemicolectomy, both small and large bowel ends were stapled, all patients underwent relook laparotomy 48 hours later where bowel viability was confirmed in all patients. Both bowel ends were exteriorized as end ileostomy and mucus fistula (double barrel stoma). Two patients had large caecal perforations, one patient had multiple perforations of the ascending colon and caecum, and one patient had a hepatic flexure perforation. All patients had ischemia of the right colon most pronounced at the caecum, none of the operated patients had ischemia of the small bowel or the rest of the colon. One patient developed post-operative intra-abdominal collection requiring image guided bed side drainage.

All four patients recovered well from COVID 19 infection, extubated and left the hospital. Two of them had their stoma reversed two and ten months post the initial surgery, one deemed high risk for reversal of stoma due to his cardiac condition and one patient lost to follow up.

All patients received steroids (hydrocortisone, methylprednisolone), Noradrenaline, hydroxychloroquine, antivirals (Favipiravir or Kaletra), one patient only received IL 6 inhibitor.



**Figure 2.** Gangrenous colon with perforation.

### 3. Discussion

Respiratory symptoms of cough, fever, dyspnea and shortness of breath are the commonly reported symptoms since the outbreak of novel coronavirus (2019-nCoV). [10]

Apart from the respiratory symptoms, gastrointestinal manifestations were reported in SARS-CoV and MERS-CoV as well as the latest SARS-CoV-2. SARS-CoV and MERS-CoV RNA were identified in stool samples in 86-100% and 15% respectively. A recent metanalysis reported 48% positive viral RNA in stool samples in patient infected with COVID-19 whether they had gastrointestinal symptoms or not. SARS-CoV-2 RNA was detected in 55% of stool samples in patient with positive nasopharyngeal swab. The likelihood of detecting the virus RNA was higher in patient who presented with diarrhea. [11]

Angiotensin converting enzyme 2 (ACE2) receptor was identified to be the entry point of SARS-CoV to the epithelial cells in the respiratory system and enterocyte in the gastrointestinal system. ACE2 found abundantly in type 2 pneumocytes in the lung, intestinal mucosa and to lesser extent in the liver and biliary tree. [12]

SARS-CoV-2 shows more than 80% structural similarity to SARS-CoV. Recent studies demonstrated the presence of SARS-CoV-2 viral nucleocapsid protein in the gastrointestinal tract. Where ACE2 receptor suggested to be the entry point for SARS-CoV-2 into the enterocytes explaining the gastrointestinal symptoms associated with the Disease. [13]

A recently published multicounty metanalysis of a total of 4,243 COVID-19 patients, reported 17.6% prevalence of gastrointestinal symptoms. Anorexia was the most common symptom of 26.8% followed by diarrhea 12.5%, nausea/vomiting 10.2% and abdominal pain/discomfort of 9.2%. The article also reported significant heterogenicity of gastrointestinal symptoms among analyzed studies. With few

patients experiencing gastrointestinal symptoms only without any respiratory symptoms during the course of the disease. [14]

Xiao *et al.*, and others were able to isolate infectious SARS-CoV-2 virions from stool, suggesting feco-oral transmission to be one of the transmission routes of the disease. Prolonged shedding of viral RNA in stool was observed up to 30 days with 70% of positively tested stool for SARS-CoV-2 RNA remain positive despite negative respiratory samples. The same results were also confirmed by other studies. [14]

Gastrointestinal symptoms most likely were overlooked in the beginning of the pandemic, and became more apparent once testing included patient presenting with non-respiratory symptoms. Another factor might be physician starting to look at infected patients as a whole instead of focusing on the respiratory system only.

Few articles suggested a positive association between gastrointestinal symptoms and disease severity. In the meta-analysis by Cheung *KS et al.*, severe disease was observed in patient who had gastrointestinal symptoms compared to patients who did not (17.1% vs 11.8%). Saying that, other studies did not demonstrate the same correlation. [15]

An article by Liu *et al.*, reported histological findings in an autopsy of the gastrointestinal tract in patients infected with SARS-CoV-2. Small bowel, esophagus and large bowel examination showed degenerated necrotic areas with mucosal shedding of varying degrees, plasma and lymphocyte infiltrate of the gastrointestinal mucosa. Viral nucleocapsid protein was detected in gastric, duodenal and rectal mucosa. In the other hand, Xiao *et al.* reported normal appearance of the gastrointestinal mucosa with no apparent damage using H&E stain. Also reported positive staining of ACE2 and SARS-CoV-2 in the gastrointestinal epithelium. [16]

With recent evidence of the presence of SARS-CoV-2 virus in the gastrointestinal epithelium, we suggest that colonic perforation can be secondary outcome of the direct invasion of SARS-CoV-2 virus to the gastrointestinal mucosa by binding to ACE 2 receptors, causing mucosal ulcer, necrosis that ends up with perforation.

In the same time, we can't rule out bowel perforation being an adverse effect of the drugs those patients are placed on, including high dose of antiviral, steroids and interleukin-6 inhibitor. It could be also a micro emboli that could not be detected on pathological examination.

## 4. Conclusion

Until recently SARS-CoV-2 infection was known to primarily targeting the lung causing pneumonia and subsequently respiratory failure. With emerging atypical symptoms and disease related non-respiratory complications, other aspect of the disease is yet to be understood. Based on pathophysiological evidence, COVID19 related spontaneous bowel perforation is due to gastrointestinal mucosal injury mediated by SARS-CoV-2 virus binding to ACE2 receptors in the enterocytes.

Ischemic bowel perforation of the right colon is one of the serious complications of COVID-19 infection that requires awareness, high index of suspicion, early diagnosis and surgical intervention.

In the light of previously revised data, there is a high suggestion of feco-oral transmission of SARS-CoV-2.

With recent published evidence of the presence of infectious virions in the stool, patient disposition and self-isolation recommendations might need to be revised to include those new findings. Those measures may aid in controlling the pandemic and preventing further waves of the disease.

## References

- [1] Wu Y, Guo C, Tang L, *et al.* Prolonged presence of SARS-CoV-2 viral RNA in faecal samples. *Lancet Gastroenterol Hepatol.* 2020. [https://doi.org/10.1016/S2468-1253\(20\)30083-2](https://doi.org/10.1016/S2468-1253(20)30083-2).
- [2] Xiao F, Tang M, Zheng X, Liu Y, Li X, Shan H. Evidence for gastroin- testinal infection of SARS-CoV-2. *Gastroenterology.* 2020. Published online Mar 3. <https://doi.org/10.1053/j.gastro.2020.02.055>.
- [3] Tian Y, Rong L, Nian W, He Y. Review article: gastrointestinal features in COVID-19 and the possibility of faecal transmission. *Aliment Pharmacol Ther.* 2020; 51: 843–851. <https://doi.org/10.1111/apt.15731>.
- [4] Paola De Nardi, Danilo C Parolini, Marco Ripa, Sara Racca, Riccardo Rosati. Bowel perforation in a Covid-19 patient: case report. *Int J Colorectal Dis.* 2020 Sep; 35 (9): 1797-1800.
- [5] Hang W, Du RH, Li B, *et al.* Molecular and serological investigation of 2019-nCoV infected patients: implication of multiple shedding routes. *Emerg Microbes Infect.* 2020; 9 (1): 386-389.
- [6] [Cheung KS, Hung IF, Chan PP, Lung K, Tso E, Liu R, Ng Y, Chu MY, Chung TW, Tam AR, Yip CC, Leung K-H, Yim-Fong Fung A, Zhang RR, Lin Y, Cheng HM, Zhang AJ, To KK, Chan K-H, Yuen K-Y, Leung WK, Gastrointestinal Manifestations of SARS-CoV-2 Infection and Virus Load in Fecal Samples from the Hong Kong Cohort and Systematic Review and Meta-analysis, *Gastroenterology* (2020), doi: <https://doi.org/10.1053/j.gastro.2020.03.065>].
- [7] ZhuN, Zhang D *et al* (2020) A novel corona virus from patients with pneumonia in China, 2019. *N Engl J Med* 382: 727–733. <https://doi.org/10.1056/NEJMoa2001017>
- [8] Yuan Tian, Long Rong, Weidong Nian, Yan He (2020) Review article: gastrointestinal features in COVID-19 and the possibility of faecal transmission *Aliment Pharmacol Ther* 51: 843-851. Published online 2020 Mar 31. doi: <https://doi.org/10.1111/apt.15731>, 843, 851.
- [9] Martin AI, Rao G. Martin AI, *et al.* Methodist Deakey Cardiovasc J. COVID-19: A Potential Risk Factor for Acute Pulmonary Embolism. 2020 Apr-Jun; 16 (2): 155-157. doi: 10.14797/mdcj-16-2-155.
- [10] Kangas-Dick A, Prien C, Rojas K, Pu Q, Hamshow M, Wan E, Chawla K, Wiesel O. Kangas-Dick A, *et al.* SAGE Open Med Case Rep. 2020 Jul 16; 8: 2050313X20940570. doi: 10.1177/2050313X20940570. E Collection 2020.

- [11] Handaya AY, Andrew J, Hanif AS, Fauzi AR. Handaya AY, et al. Covid-19 mimicking symptoms in emergency gastrointestinal surgery cases during pandemic: A case series. *Int J Surg Case Rep.* 2020 Oct 24; 77: 22-27. doi: 10.1016/j.ijscr.2020.10.064. e Collection 2020.
- [12] Rojo M, Cano-Valderrama O, Picazo S, Saez C, Gómez L, Sánchez C, Sanz-Ortega G, Torres AJ. Intestinal perforation in patient with COVID-19 infection treated with tocilizumab and corticosteroids. Report of a clinical case. 2021 Feb; 99 (2): 156-157. doi: 10.1016/j.ciresp.2020.04.030. Epub 2020 Apr 29.
- [13] Giuffrè M, Bozzato AM, Di Bella S, Occhipinti AA, Martingano P, Cavallaro MFM, Luzzati R, Monica F, Cova MA, Crocè LS. Giuffrè M, et al. Spontaneous Rectal Perforation in a Patient with SARS-CoV-2 Infection. *J Pers Med.* 2020 Oct 8; 10 (4): 157. doi: 10.3390/jpm10040157.
- [14] Kotfis K, Skonieczna-Żydecka K. COVID-19: gastrointestinal symptoms and potential COVID-19: gastrointestinal symptoms and potential sources of 2019-nCoV transmission. *Anaesthesiol Intensive.* 2020; 52: 1. doi: 10.5114/ait.2020.93867.
- [15] Jin X, Lian J-S, Hu J-H. Epidemiological, clinical and virological characteristics of 74 cases of coronavirus-infected disease 2019 (COVID-19) with gastrointestinal symptoms. *Gut.* 2020; 0: 1–8. doi: 10.1136/gutjnl-2020-320926.
- [16] Gu Jinyang, Han Bing, Wang Jian. COVID-19: Gastrointestinal Manifestations and Potential Fecal–Oral Transmission. *Gastroenterology.* 2020; 158 (6): 1518–1519. doi: 10.1053/j.gastro.2020.02.054.