



Double Pigtail to Manage Pericardial Rupture of Left Lobe Liver Abscess

Gautam Shubhankar, Ashutosh Nagpal*, Gautam Anand, Deborshi Sharma

Department of General Surgery, Lady Hardinge Medical College, New Delhi, India

Email address:

ashutosh.nn@gmail.com (A. Nagpal)

*Corresponding author

To cite this article:

Gautam Shubhankar, Ashutosh Nagpal, Gautam Anand, Deborshi Sharma. Double Pigtail to Manage Pericardial Rupture of Left Lobe Liver Abscess. *Journal of Surgery*. Vol. 9, No. 4, 2021, pp. 149-152. doi: 10.11648/j.js.20210904.11

Received: May 3, 2021; **Accepted:** June 1, 2021; **Published:** June 9, 2021

Abstract: Background: Liver abscess if left untreated can rupture into adjoining pleura, pericardium, peritoneum. Rupture into pericardium, though very rare, is a dreaded complication and worsens the prognosis. Presentation here can be nonspecific. Rupture into pericardium if associated with cardiac tamponade often requires pericardiotomy. Case information: A 16-year boy presented with epigastric pain, fever and recent onset chest discomfort. No signs of cardiac tamponade were seen on clinical examination. Investigations revealed a left lobe liver abscess rupturing into pericardium and asymptomatic pericardial effusion. Serological testing confirmed the etiology to be amebic. The condition was using pigtail catheter drainage in both the pericardial cavity and hepatic abscess. Discussion: Ruptured liver abscess occurs more commonly due to delay in diagnosis. It increases the severity of disease depending upon the site of rupture. Pericardial rupture is the most feared complication out of these. Published literature lacks reports of asymptomatic pericardial rupture of liver abscess, and management options. Available literature reports invariable requirement of surgical drainage for this entity. This report shows that lesser invasive drainage procedures can successfully resolve this dreaded complication. Conclusion: Amoebic liver abscess rupturing into pericardium can be asymptomatic. Successful management with percutaneous drainage and double pigtail catheters offers resolution and avoids morbidity associated with surgical drainage.

Keywords: Amoebic Liver Abscess, Pericardial Rupture, Pigtail Catheter Drainage

1. Introduction

Amebic liver abscess is the most common extra intestinal manifestation of amebiasis. Ingestion of food and water contaminated with *E. histolytica* causes the production of potentially invasive trophozoites. These trophozoites damage the colonic epithelium thus invading colon, subsequently spreading to extra intestinal sites such as the liver by ascending through the portal circulation causing liver abscess. [1, 2] In most patients, particularly those under 30 years of age and children, the clinical presentation and course of disease are typical. The onset is abrupt, with pain in the upper abdomen and high fever. The pain is intense and constant, radiating to the scapular region and right shoulder; it increases with coughing, deep breathing or when the patient rests on the right side. When the abscess is located in the left lobe, the pain tends to be felt in the epigastrium and may radiate to the left shoulder. Fever is present in most cases; it

varies between 38 °C and 40 °C (100–104 °F), frequently in spikes, but is sometimes constant over several days, with rigors and profuse sweating. There is anorexia and rapid weight loss; one-third of patients have nonproductive cough. Nausea and vomiting may occur and in some cases there may be diarrhea or dysentery. Physical examination reveals a pale wasted patient with tender hepatomegaly. Digital pressure in the right lower intercostal spaces produces intense pain and there is often marked tenderness on percussion over the right lower ribs in the posterior region. Movement of the right side of the chest and diaphragm is greatly restricted, as is the intensity of respiratory sounds. Older patients may present with a chronic and milder nonspecific febrile illness, hepatomegaly, anemia and abnormal liver function tests. If a space-filling defect in the liver is observed, the differential diagnosis includes (1) amebiasis (most common in men with a history of travel or residence in a developing country; (2) pyogenic or bacterial abscess (suspected in women, patients

with cholecystitis, elderly patients, individuals with diabetes, and patients with jaundice); (3) echinococcal abscess (an incidental finding, inasmuch as echinococcal abscess should not cause pain or fever); and (4) cancer. Most patients with amebic liver abscess have detectable circulating antigen in serum, as well as serum antiamebic antibodies.

In children, abdominal pain is reported infrequently with amebic liver abscess. More commonly, high fever, abdominal distention, irritability, and tachypnea are noted. Some of these children are admitted to the hospital with a fever of unknown origin.

If treatment is delayed, the abscess can rupture into the adjacent organs and cavities, most often into peritoneal and pleural cavities. Liver abscess rupture is more commonly reported with amebic as compared to pyogenic abscesses. [15] Rupture of liver abscess as a complication, is associated with threefold increase in mortality. [9] Presentation, clinical course and prognosis varies vastly depending on the site of rupture. Advances in imaging technology have made both early diagnosis and less invasive interventions possible.

Rupture into the pericardium is a very rare complication of amebic liver abscess. It usually occurs from left lobe abscesses due to their close proximity to the pericardium. It can further cause cardiac tamponade, consequently requiring urgent drainage, and associated drastically increased mortality. Published literature till date has no records about the exact incidence of this complication, and lack clear guidelines regarding management of this entity. [3, 4, 8-13]

We report a unique case of pericardial rupture of an amebic liver abscess, managed successfully by pericardiocentesis with pericardial pigtail and hepatic pigtail insertion along with broad spectrum antibiotics.

2. Case Report

A 16-year boy presented to emergency after having chest discomfort. His illness began 4 days prior, with progressive epigastric pain and low-grade fever. Tachycardia was the only significant finding on general examination. Cardiovascular and respiratory exam was normal. On palpation, abdomen revealed tender hepatomegaly. Total count was $14000/\text{mm}^3$ with neutrophilia. Liver function tests were normal. His chest X-ray showed cardiomegaly, and electrocardiogram revealed sinus tachycardia with low voltage complexes. Abdominal ultrasonogram showed hepatomegaly and hypoechoic left liver lobe lesion of 236cc likely abscess, with a rent of 1.6 cm in the diaphragm and rupture of abscess into pericardial cavity along with bilateral pleural effusion. Trans thoracic echocardiogram showed a large pericardial effusion, 3.2 cm anteriorly and 2.8 cm posteriorly, continuous with left lobe liver abscess. Serological test for amebiasis was positive confirming the etiology.

An emergency pericardiocentesis was performed and 500 ml of thick anchovy sauce pus was drained. Pericardial pigtail catheter was placed which drained 50 ml seropurulent fluid over the next two days. Patient was kept on Piperacillin-

Tazobactam & double dose Metronidazole. Fluid input output monitoring was done. High protein diet was advised and adequate chest physiotherapy ensured. CECT chest and abdomen was done. A guided pigtail catheter was placed in the liver abscess, thus draining the source. Hepatic pigtail drained 200ml anchovy sauce pus over 3 days. After 48 hrs. of pericardiocentesis, repeat echocardiogram showed minimal pericardial effusion and the pericardial pigtail catheter was hence removed. Patient's TLCs became normal with normal heart rate. Repeat abdominal ultrasonography revealed a collapsed abscess site in the liver, hence hepatic pigtail was removed thereafter. His symptoms gradually improved after 3 days and was later discharged.

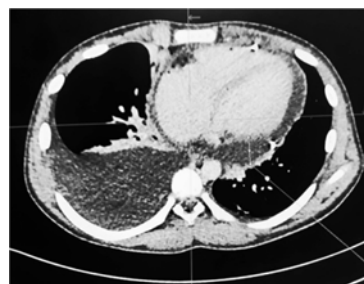

Figure 1. Axial CT image showing pericardial effusion.

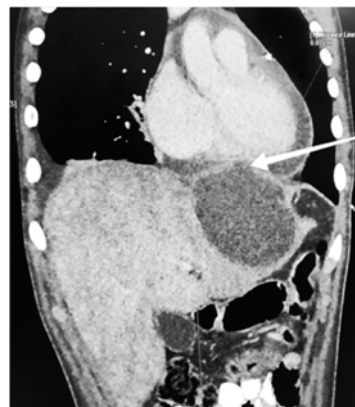


Figure 2. Coronal Image with large abscess cavity in left lobe along with pericardial effusion. Rent in diaphragm marked by arrow.

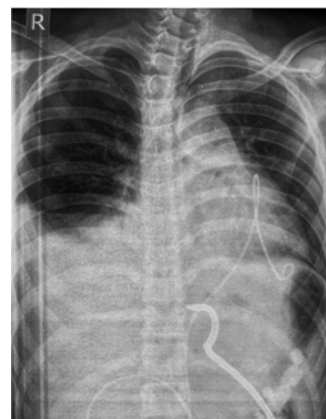


Figure 3. X-ray chest with upper abdomen showing pericardial and hepatic pigtail catheters.

3. Discussion

Entamoeba is a leading cause of dysentery in the tropics. Transmission occurs via feco-oral route, with ingestion of viable cysts. About 10% of the world population is infected with various Entamoeba species. Amebiasis results from *E. histolytica* and is the third most common cause of parasite related deaths worldwide. Male sex and HIV infection are two most important risk factors associated with invasive amebiasis and liver abscess. [16] Hepatic involvement occurs following invasion of *E. histolytica* into mesenteric venules. Amoebae travel to the liver (right lobe more commonly) via the portal circulation where they typically form large abscesses. Amebic liver abscess usually presents with chronic low grade fever, abdominal pain, and emaciation. These abscesses, on timely detection, can be managed medically. If left untreated these abscesses can rupture into adjoining pleura, pericardium, peritoneum or even stomach. [5, 6] Ruptured abscess invariably requires drainage and often requires operative interventions. Thus the associated prolonged hospital stays and increased morbidity and mortality.

Two large case series of hepatic amebic abscesses have been published. The first study was by Carlos et al. who examined 501 cases of amebic liver abscess over 18 years. Out of these, there were 326 cases of rupture through the diaphragm with only 5 cases (0.01%) rupturing into the pericardium and just one case rupturing into both pleural and pericardial cavities. [8] The second study was from China by Meng et al. who reported 503 cases of amebic liver abscess over 21 years. Twenty two percent of the cases developed complications due to perforation. Rupture into the pericardial cavity was a very rare complication in both the studies.

Multiple case reports and series, report pericardial rupture of liver abscess to be rare. [3, 4, 8-10] Rao *et al.* in 2009 reported a rare case of liver abscess rupturing into pleural, pericardial, peritoneal cavities with gastric rupture. [7]

Treatment of amebic liver abscess depends on its severity and associated complications. In the absence of consensus guidelines, patients with liver abscess are managed as per the attending physician. In general, uncomplicated amebic liver abscesses <5 cm are managed medically, while abscesses >5 cm are treated by percutaneous intervention in addition to antibiotics. Other common indications requiring intervention are left lobe abscess, impending rupture (<1 cm from liver margin) and no response to antibiotic therapy. [14] Common drainage procedures include percutaneous needle aspiration and pigtail catheter drainage. Rupture into pleura requires intercostal drainage tube placement. Intraperitoneal rupture requires peritoneal drain placement and may require laparotomy depending upon the clinical picture. Reported cases of pericardial rupture almost invariably require surgical management in form of thoracotomy and/or pericardial window. [10-13]

Certain features make this case a unique one. The patient

presented with pain in lower chest and epigastrium with low grade fever, in spite of liver abscess rupturing into pericardium with bilateral pleural effusion. No clinical features suggestive of pericardial tamponade were present during the entire course of disease. Clinical picture was vague and definitely not in line with the ongoing disease process. In our case pericardial pigtail catheter served for emergency drainage of pericardial collection, and hepatic pigtail served in draining the source. This may suggest that at early presentation, patients with pericardial rupture of liver abscess have mild symptoms. High index of clinical suspicion is required for early diagnosis and prevention of devastating consequences. Pigtail catheter drainage avoids morbidity associated with the surgical drainage procedures.

4. Summary

Pericardial rupture of liver abscess is a rare entity. In addition it may have nonspecific presentation further complicating the picture, as highlighted in this case report. High index of suspicion is required to diagnose this dreaded complication, especially in abscesses involving the left lobe. Timely diagnosis and drainage can prevent life threatening sequelae like cardiac tamponade. Less invasive intervention ie pigtail catheter drainage offer lesser procedure related morbidity and can successfully manage this condition, as has been done in our case.

References

- [1] Albenmoussa A. et al. Liver abscess presentation and management in Saudi Arabia and the United Kingdom. *Ann Saudi Med.* 2011 Sep Oct; 31 (5): 528-32.
- [2] Wuerz T. et al. A review of amebic liver abscess for clinicians in a nonendemic setting. *Can. J. Gastroenterol.* 2012 Oct; 26 (10): 729-33.
- [3] Gupta V. et al. Amoebic liver abscess ruptured into pericardium. *Indian Heart J* 1980; 32: 113-7.
- [4] Suryanarayan K. et al. Amoebic pericarditis. Report of 2 case *Indian Heart J* 1974; 26: 241-5.
- [5] Blazquez S. et al. Initiation of inflammation and cell death during liver abscess formation by *Entamoeba histolytica* depends on activity of the galactose/N-acetyl-D-galactosamine lectin. *Int J Parasitol* 2007; 37: 425: 33.
- [6] Stanley SL Jr. Amoebiasis. *Lancet* 2003; 361: 1025-34.
- [7] Rao S. et al. Hepatic amoebiasis: A reminder of the complications. *Curr Opin Pediatr* 2009; 21: 145-9.
- [8] Ibarra-Perez C. Thoracic complications of amebic abscess of the liver: Report of 501 cases. *Chest* 1981; 79: 672-7.
- [9] Meng XY, Wu JX. Perforated amebic liver abscess: Clinical analysis of 110 cases. *South Med J* 1994; 87: 985-90.
- [10] Ibarra-Pérez C. et al. Rupture of amebic liver abscess into the pericardial cavity. Report of 11 cases. *Prensa Med Mex* 1972; 37: 242-5.

- [11] Francis, Cliojis, et al. "A case report of ruptured amoebic liver abscess causing cardiac tamponade and requiring pericardial window." *European Heart Journal: Case Reports* 4.5 (2020): 1.
- [12] Prateepchaiboon, Tanaporn, et al. "A rare case of massive pericardial effusion due to spontaneous rupture of *Streptococcus anginosus* group liver abscess." *Clinical Journal of Gastroenterology* 13.6 (2020): 1258-1264.
- [13] Chandran, Suresh R., et al. "Amebic hepatopericardial fistula causing cardiac tamponade." *Annals of Tropical Medicine and Public Health* 5.4 (2012): 387.
- [14] Jindal, Ankur, et al. "Management Practices and Predictors of Outcome of Liver Abscess in Adults: A Series of 1630 Patients from a Liver Unit." *Journal of Clinical and Experimental Hepatology* 11.3 (2021): 312-320.
- [15] Chong, V H et al. "Rare complications of pyogenic liver abscess." *Singapore medical journal* vol. 51, 10 (2010): e169-72.
- [16] Fauci, Anthony S. *Harrison's principles of internal medicine*. McGraw-Hill Education, 2015.