



# Large Locking Fusion Plate and Cable Fixation in the Treatment of Periprosthetic Femoral Fracture (PFF) After Total Hip Arthroplasty

Dong Fei<sup>1,\*</sup>, Tong Kai<sup>2</sup>, Zhang Tongren<sup>1</sup>, Li Aiguo<sup>1</sup>

<sup>1</sup>Department of Orthopedics, Guangzhou Red Cross Hospital, Jinan University, Guangzhou, China

<sup>2</sup>Department of Orthopedics, Zhongnan Hospital, Wuhan University, Wuhan, China

## Email address:

[dongfei304@163.com](mailto:dongfei304@163.com) (Dong Fei)

\*Corresponding author

## To cite this article:

Dong Fei, Tong Kai, Zhang Tongren, Li Aiguo. Large Locking Fusion Plate and Cable Fixation in the Treatment of Periprosthetic Femoral Fracture (PFF) After Total Hip Arthroplasty. *Journal of Surgery*. Vol. 10, No. 2, 2022, pp. 89-94. doi: 10.11648/j.js.20221002.18

Received: April 7, 2022; Accepted: April 21, 2022; Published: April 28, 2022

---

**Abstract:** *Objective* To investigate the clinical effect of large locking fusion plate and cable fixation in the treatment of Periprosthetic femoral fracture (PFF) after total hip arthroplasty (THA). *Methods* Clinical data of 15 cases of PFF after THA treated with large locking fusion plate and cable fixation from June 2012 to June 2019 in our hospital were retrospectively analyzed. These cases included 4 males and 11 females, whose age were 61-82 years old, with an average age of 71.3 years, 6 cases on the left side and 9 cases on the right side. We performed total hip arthroplasty in 10 patients and hemiarthroplasty in 5 patients. There were 5 cases of Type B1 fracture, 8 cases of type B2 fracture, and 2 cases of type B3 fracture. Preoperative and postoperative hip function, HSS score, Harris score and surgical complications were observed and evaluated. *Results* 15 patients were followed up 15-77 months after the operation (mean 36.9 months), and the hip function was significantly improved. The preoperative HSS score of knee function was  $4.13 \pm 1.69$ , and the postoperative HSS score of knee function was  $90.93 \pm 3.06$ , with 11 excellent cases, 4 good cases and 0 general cases, with an excellent rate of 100%. Preoperative Harris score of knee function was  $3.73 \pm 1.16$ . Harris score of hip function was  $89.33 \pm 3.73$  at the last follow-up. Among of all Harris scores, 10 cases were excellent, 3 cases were good, and 2 cases were general, with an excellent rate of 86.7%. Postoperative HSS and Harris scores were higher than those before surgery ( $P=0.031$ ,  $P<0.001$ ). No blood vessel or nerve injury occurred during the operation. During the postoperative follow-up, no complications such as periprosthetic infection, loosening, dislocation, nonunion of fracture and refracture occurred in 14 cases, and one case suffered refracture after the operation, which was healed after the nail and stick system fixation. *Conclusion* The application of large locking fusion plate and cable in the treatment of femoral periprosthetic fractures after total hip arthroplasty is simple, easy to operate, less complications, satisfactory clinical results, and worthy of promotion.

**Keywords:** Periprosthetic Femoral Fractures, Vancouver B Type, Total Hip Arthroplasty, Hip Function Score

---

## 1. Introduction

With the widespread clinical development of hip arthroplasty, a series of postoperative complications have gradually attracted the attention of orthopedic surgeons. Periprosthetic femoral fracture (PFF) has become the third leading cause of hip revision, rank only second to infection and aseptic loosening [1]. The incidence of PFF is increasing, which seriously affects the quality of life of patients. Due to the particularity and complexity of PFF, it involves the field

of trauma and joints, which has become one of the difficult points in the clinical research of joint surgery. The Vancouver classification system is currently the most widely used clinical classification system for PFF. The location of the fracture, characteristics of the fracture, stability of the prosthesis and femoral bone loss are comprehensively considered to classify the fracture types [2]. Vancouver B-type fractures are femoral shaft fractures close to the hip

joint prosthesis. According to whether the femoral fracture is stable and whether there is bone loss, it is divided into three subtypes, B1, B2, and B3 [3]. Because the prosthesis is placed in the femoral medullary cavity, and most elderly patients are accompanied by osteoporosis, it is often difficult to fix the fracture. In the past, the proximal end of femoral fracture was mostly fixed by titanium cables, steel wires, and locking plates. Clinical studies and biomechanical experiments found that due to insufficient fixation strength at the proximal end of the fracture, the postoperative fixation failure rate was as high as 30%-43% [4]. Which fixation method is used in the clinic is still full of controversy. Therefore, this study summarized the clinical data of 15 cases of PFF after total hip arthroplasty (THA) treated with large locking fusion plate and cable fixation in our hospital from June 2012 to June 2019 for retrospective analysis to provide solutions for the treatment of PFF of Vancouver B type.

## 2. Materials and Methods

### 2.1. General Information

Inclusion criteria: (1) a clear history of hip arthroplasty surgery and successful operation; (2) a clear diagnosis of PFF. Exclusion criteria: (1) Pathological fracture; (2) Prosthesis loosening found in intraoperative examination; (3) Patients with other diseases who could not tolerate surgery and received conservative treatment; (4) Case data was incomplete or lost to follow-up Case.

A total of 15 patients with Vancouver B-type PFF were enrolled from June 2012 to June 2019, including 4 males and 11 females; the age ranged from 61 to 82 years, with an average of 71.3 years. There were 6 cases on the left side and 9 cases on the right side. There were 10 cases after THA and 5 cases after hemiarthroplasty. (See Table 1 for details).

*Table 1. General information of 15 patients.*

Cases	Gender	Age	Injury factors	affected side	osteoporosis	fracture type	Prosthetic type (first time)	Prosthetic type (revision surgery)	bone grafting	Time since the first replacement (month)	monitoring time interval (month)
1	female	82	tumble	Right hip	Yes	B1	Biological prosthesis	Revision biological femur prosthesis	No	77	30
2	female	74	no obvious causes	Right hip	Yes	B2	Biological prosthesis	Revision biological femur prosthesis	Yes	69	77
3	female	80	tumble	Right hip	undetected	B1	Biological prosthesis	Revision bone cement femoral prosthesis	No	58	65
4	female	73	tumble	Right hip	Yes	B1	Biological prosthesis	Revision bone cement femoral prosthesis	Yes	25	40
5	female	64	tumble	Right hip	Yes	B2	Bone cement type prosthesis	Revision bone cement femoral prosthesis	Yes	80	38
6	female	68	tumble	left hip	Yes	B2	Biological prosthesis	Revision biological femur prosthesis	Yes	16	29
7	man	61	tumble	left hip	No	B1	Bone cement type prosthesis	Revision biological femur prosthesis	Yes	24	32
8	man	63	no obvious causes	left hip	Yes	B2	Biological prosthesis	Revision biological femur prosthesis	Yes	10	15
9	female	71	tumble	Right hip	Yes	B1	Biological prosthesis	Revision biological femur prosthesis	Yes	17	20
10	man	69	tumble	Right hip	undetected	B2	Biological prosthesis	Revision biological femur prosthesis	No	27	38
11	female	73	tumble	left hip	Yes	B2	Biological prosthesis	Revision bone cement femoral prosthesis	Yes	35	27
12	female	81	no obvious causes	left hip	Yes	B3	Bone cement type prosthesis	Revision biological femur prosthesis	Yes	41	34
13	man	65	tumble	Right hip	Yes	B2	Bone cement type prosthesis	Revision biological femur prosthesis	No	21	29
14	female	75	tumble	left hip	undetected	B3	Biological prosthesis	Revision biological femur prosthesis	Yes	32	39
15	female	70	no obvious causes	Right hip	Yes	B2	Biological prosthesis	Revision biological femur prosthesis	Yes	30	41

## 2.2. Clinical Protocol

### 2.2.1. Preoperative Preparation

After admission, patients underwent skin traction and immobilization, and the traction weight was 2 kg. Preoperative examinations and preparations were completed as soon as possible, full-length X-ray radiography of the femur and CT examination were performed, laboratory examinations were performed to rule out infections. Surgical tolerance assessment and supportive treatment were carried out. For elderly patients, blood pressure, blood sugar and other basic diseases were controlled, VAS pain score evaluation and analgesia were performed to prevent deep vein thrombosis of lower extremities, and surgical-related contraindications were excluded.

### 2.2.2. Surgical Methods

The patient was supine and the lateral femoral approach of the hip joint was taken with combined spinal-epidural anesthesia, and the hip joint was exposed and dislocated. The femoral prosthesis and the fractured end were fully exposed. During the operation, the loosening of the femoral prosthesis and the bone quality were confirmed again. If necessary, the acetabulum was fully exposed and the acetabular bed was grinded, and the acetabular prosthesis was placed or replaced. The femoral prosthesis was removed, the bone cement and medullary cavity plug in the femoral medullary cavity were completely removed, the fracture was reduced and temporarily fixed, perform the femoral reaming and insert an elongated femoral stem of appropriate size and length. 4 cases are cemented long Stem prostheses, 11 cases were biological long-stem prostheses. The temporarily fixed cerclage steel wire was removed, appropriate plate with ZIMMER cable system was placed on the lateral side of the femur. If the medial stability needs to be strengthened, the allogeneic bone was grafted on the medial or anterior side of the femur, wire or titanium cable was used to strengthen it. Mono-cortical and double cortical locking screws were fixed at the proximal and distal ends of the prosthesis, then 2 or 3 sets of titanium cables were circulated at the proximal end of the prosthesis, and the pressure of the titanium cable was adjusted.

### 2.2.3. Postoperative Treatment

Routine antibiotics were performed to prevent infection for 3-5 days after operation, anti-osteoporosis treatment was performed, physical methods combined with drugs were performed to prevent deep vein thrombosis of the lower extremities. On the second day after the operation, passive rehabilitation exercise of hip and knee joints can be performed after oral anti-inflammatory and analgesic drugs or intramuscular injection of Parecoxib Sodium. Active flexion and extension of hip, knee and lower limb muscle strength rehabilitation training can be started 2 weeks after surgery. Postoperative X-rays were regularly performed to evaluated the fracture union. After the fracture was healed well, rehabilitation training with full weight-bearing was gradually performed on the affected limb.

## 2.3. Evaluation Criteria

Preoperative and postoperative hip function was assessed according to the HSS [5] and Harris hip joint score table [6, 7]. Osseous evaluation results: excellent to obtain osseous union, no infection, deformity, etc., limb length <2cm; good to obtain osseous union and any 2 other items; fair to obtain osseous union and any 1 item. Hip joint function results: excellent for daily self-care without 4 items in the osseous results; good for daily life self-care with any 1 or 2 items in the osseous results, fair for daily life self-care with 3 or 4 items in the osseous results or amputation; poor for no daily life self-care. Comprehensive scoring results: HSS and Harris scores of 90-100 points are considered excellent, HSS and Harris scores of 85-90 points are considered good, and HSS and Harris scores of 80-85 points are considered fair.

## 2.4. Statistical Methods

Statistical analysis was performed on the collected data using SPSS 19.0 statistical software. All descriptive analysis and measurement data were expressed as mean  $\pm$  standard deviation ( $\bar{x} \pm s$ ). Two independent-sample t-tests or rank sum tests are used to assess differences between groups. A P value of < 0.05 was defined as a statistically significant difference.

## 3. Results

### 3.1. General Clinical Results

All 15 patients in this group were followed up for 15-77 months, with an average of 36.9 months. The time from fracture to the first artificial joint replacement was 10-80 months, with an average of 30.9 months. There were 6 cases on the left side of the hip and 9 cases on the right side. Reasons for fractures: 9 cases were injured by falls and 6 cases had no obvious history of trauma. PFF were classified according to Vancouver classification: 2 cases of type B1, 5 cases of type B2, and 2 cases of type B3. Types of prostheses for the first replacement surgery: 4 cases of cemented prostheses and 11 cases of biological prostheses; the types of prostheses used for revision in the second operation: 4 cases of revision bone cement prostheses and 11 cases of revision biological prostheses. There were 11 patients with osteoporosis, 3 cases were undetected, and 1 case had no osteoporosis. (For details, see Table 1).

### 3.2. Fracture Healing

The fractures of all patients healed, and the healing time of fracture was 3-8 months, with an average of 4.3 months (see Figure 1 for typical cases). No vascular and nerve injury occurred during the operation. During the postoperative follow-up period, 14 cases had no complications such as infection, loosening, dislocation, fracture nonunion, and re-fracture. One case had re-fracture after surgery, which healed after changing to rod system fixation.

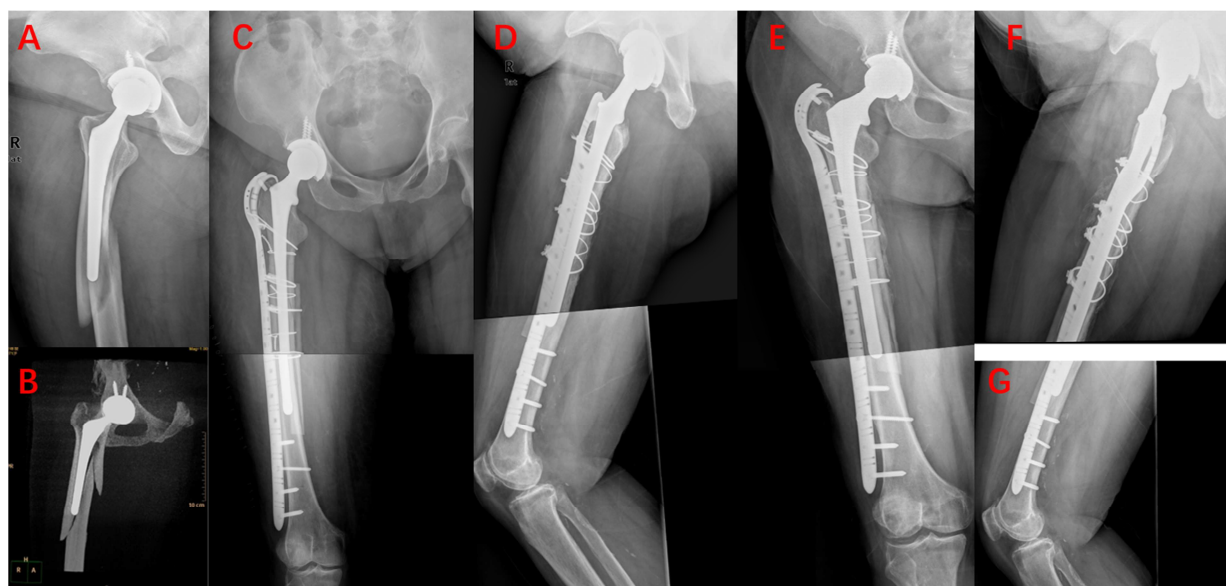
### 3.3. Clinical Efficacy

The preoperative HSS score of hip joint function was  $4.13 \pm 1.69$  points, and the postoperative HSS score of hip joint function was  $90.93 \pm 3.06$  points. 11 cases were excellent, 4 cases were good, 0 cases were fair, and the excellent and good rate was 100%. The preoperative Harris score of hip

joint function was  $3.73 \pm 1.16$  points, and the Harris score of hip joint function at the last follow-up was  $89.33 \pm 3.73$  points. There were excellent in 10 cases, good in 3 cases, and fair in 2 cases. The excellent and good rate was 86.7%. The postoperative HHS and Harris scores were higher than those before surgery ( $p < 0.001$ ). See Table 2 and Figure 2 for details.

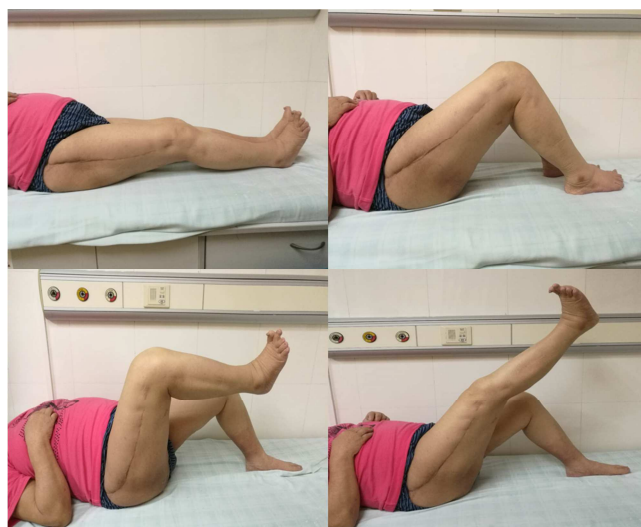**Table 2.** Comparison of HSS score and Harris hip score before and after surgery ( $\bar{x} \pm s$ ).

fracture type	pre-operation HSS score	Postoperative HSS score	Statistical P value	Pre-operation harris score	Postoperative harris score	Statistical P value
total (n=15)	$4.13 \pm 1.69$	$90.93 \pm 3.06$	$<0.001$	$3.73 \pm 1.16$	$89.33 \pm 3.73$	$<0.001$
B1 (n=5)	$4.80 \pm 0.84$	$90.20 \pm 3.96$	$<0.001$	$3.20 \pm 1.10$	$87.20 \pm 3.83$	$<0.001$
B2 (n=8)	$4.00 \pm 2.07$	$91.63 \pm 2.45$	$<0.001$	$4.13 \pm 1.25$	$90.00 \pm 2.98$	$<0.001$
B3 (n=2)	3	90	—	3.5	92	—



**Figure 1.** Image data of fractures around the Vancouver B2 femoral prosthesis.

Images A and B respectively show the frontal X-ray of the fracture around the prosthesis after the first artificial hip replacement. C and D show the AP and lateral X-rays of the patient at 1 month after revision. E, F, G shows the patient's X-ray on 1.5 years after revision.



**Figure 2.** General photo of the patient's hip joint function on 1.5 years after revision.

## 4. Discussion

PFF is one of the common complications after THA, with an incidence of 0.1%-2.1% [8, 9]. The clinical treatment of PFF often involves the treatment of fractures and bone defects, which makes orthopedic surgeons very confusedly. The choice of surgical procedure after PFF often determines whether the fracture end can achieve good stability, which is closely related to the stability of the prosthesis and the recovery of hip joint function after surgery [4]. Among all PFF cases, Vancouver type B PFF has the highest incidence [10, 11], which mainly occurs at the tip of the prosthetic stem or the distal end adjacent to the prosthesis. The surgical treatment strategy is based on the stability of the prosthetic stem. For stable Vancouver B1 type prosthetic stem fractures, open reduction and internal fixation is the standard treatment plan. Common internal fixation methods include intramedullary nails. Cable steel plate, common plate, locking compression plate, locking attachment plate,

embracing device, etc.; for the unstable Vancouver B2 or 3 fracture of the femoral stem, joint revision surgery is required, and bone grafting is according to the condition of osteoporosis [12]. The difficulty in the treatment of Vancouver B fracture is due to the existence of the prosthetic stem, the proximal end of the fracture can only be fixed with a single cortical screw, which has insufficient fixation strength, and the screw easily damages the cement cuff and the prosthesis-bone interface, thereby affects the stability of the prosthesis. The proximal end of the locking plate with cable can well match the anatomical shape of the proximal femur. The locking nail has angular stability and little interference to the periosteum. LISS can be used to act as an internal fixation bracket. The locking plate combined cable is the strongest one among many internal fixation methods [13].

Advanced age is the main risk factor for PFF after THA. In this group of cases, the average age of patients is 71.3 years. The incidence of peripheral PFF in patients older than 70 years of initial replacement is 2.9 times than that of patients under 70 years of age. The incidence of 80-year-old patients is 4.4 times than that of patients under 80 years of age [14]. Excluding the cases of undetected bone density, the cause of injury was 73.3% (11/15) of falls and 91.7% (11/12) of osteoporosis, which is consistent with the report in the literature [15], and the PFF is mostly low violence of energy is caused by falls, and its risk factors include osteoporosis. The postoperative re-fracture rate was 6.7% (1/15), which may be caused by the increase in bone fragility caused by the patient's advanced age and osteoporosis. The fractures of all patients were healed, and the fracture healing time was 3-8 months. Stable internal fixation and early rapid rehabilitation training were beneficial to the healing of fractures. In this group of 15 revision cases, 11 cases were used revision biological long-stem prosthesis. Clinically, lengthened femoral stem prostheses are routinely used for revision treatment, but biological long-stem prostheses are currently recommended. For type B1 fractures, open reduction and internal fixation with locking plates are advocated. The locking plate has good angular stability and axial stability, especially for elderly patients with osteoporotic fractures, which has good anti-torsion and anti-rotation force, which is more in line with the biological fixation mode. The first task in the treatment of B2 fractures is to restore the stability of the prosthesis, and then consider the rigid internal fixation of the fracture [16]. Compared with cemented prostheses, biological prostheses are more prone to PFF [17]. It was found that 73.3% (11/15) of this group of cases used biological prostheses for the first artificial joint replacement. For type B3 fractures, due to the loosening of the prosthesis stem, there is a large amount of bone loss at the fracture end, and the difficulty and risk of the operation are significantly increased [18]. For this type of fracture, it is recommended to fix with steel plate combined with steel wire banding and bone allograft to improve the strength of fixation during revision surgery [19]. Of the 15 patients in this study, 14 cases healed smoothly, and 1 case had re-fractures after surgery. The nail and rod system was changed to fixation and

healed. The analysis considers that the fracture type may be type B1, and allogeneic cancellous bones were implanted during the operation. Insufficient medial support, local stress concentration leads to the change to bone plate binding and fixation to increase the stability of medial support and heal.

Based on the literature [11, 15, 20, 21] combined with clinical experience, the author summarizes the experience of PFF prevention and treatment as follows: 1. The causes of fractures around the prosthesis mainly include advanced age, osteoporosis, and basic diseases. Elderly patients usually have primary or secondary osteoporosis, postoperative hip muscle strength decreases, movement coordination decreases, bone defects, prosthesis loosening, and osteolysis cause local stress around the prosthesis to increase; 2. Developing a detailed surgical plan before surgery, measuring the size of the medullary cavity, and choosing an appropriate size prosthesis to effectively avoid the local stress concentration caused by the poor position of the femoral prosthesis, thereby reducing the occurrence of PFF; 3. For patients with osteoporosis, Anti-osteoporosis treatment is very necessary during the perioperative period; 4. During the operation, violence, forced traction, and twisting of the femur must be avoided. It must be fully loosened. If necessary, it is necessary to perform osteotomy of the greater trochanter of the femur, and insert a test mode or prosthesis along the direction of the medullary cavity. When encountering resistance, the cause must be carefully looked for; 5. It is most important to use a long stem prosthesis during revision. The end of the prosthesis should reach a distance of 2 times the width of the femur from the fracture line. At the same time, it is necessary to prevent excessive stress concentration; 6. Patients were encouraged to carry out active functional exercises in the early postoperative period and timely follow-up to find and correct problems in time can reduce the occurrence of complications. For the treatment strategy of Vancouver B fracture, the following considerations should also be considered: 1. Whether the surgical plan and intraoperative alternatives are clear before the operation; 2. What kind of fixation method should be chosen (revision prosthesis combined with cable or plate, etc.) 3. What kind of prosthesis and length of femoral stem should be chosen for revision; 4. Whether elderly patients are treated for anti-osteoporosis and whether bone grafting is needed during surgery; 5. How to achieve rapid functional rehabilitation training after surgery.

There are still shortcomings in this study: 1. Due to sample size limitations and individual differences between patients, the results may be biased; 2. The follow-up time is short, and the long-term function needs further follow-up evaluation.

## 5. Conclusion

In summary, periprosthetic fracture of femur after hip arthroplasty combined with severe osteoporosis poses severe challenges to clinicians for surgical fixation due to poor local bone conditions. Active perioperative anti-osteoporosis treatment and early postoperative functional rehabilitation exercises are recommended during the perioperative period.

The application of large locking fusion plate and cable in the treatment of PFF after THA is simple and easy to operate, with few complications, satisfactory clinical results, which is worthy of promotion.

## References

- [1] Malchau H, Herberts P, Eisler T, et al. The Swedish Total Hip Replacement Register [J]. *J Bone Joint Surg Am*, 2002, 84-A Suppl 2: 2-20.
- [2] Surgical treatment of Vancouver type B periprosthetic femoral fractures [J].
- [3] Duncan C P, Masri B A. The role of antibiotic-loaded cement in the treatment of an infection after a hip replacement [J]. *Instr Course Lect*, 1995, 44: 305-313.
- [4] Qi Haotian, Sun Yuxi, Tian Wei, et al. Clinical efficacy of peripheral femoral prosthetic fracture locking plate in the treatment of Vancouver B1 type peripheral femoral prosthetic fractures [J]. *Chongqing Medicine*, 2019, 48 (16): 2804- 2807.
- [5] Marshall J L, Fetto J F, Botero P M. Knee ligament injuries: a standardized evaluation method [J]. *Clin Orthop Relat Res*, 1977 (123): 115-129.
- [6] Lau B C, Scribani M, Lassiter T, et al. Correlation of Single Assessment Numerical Evaluation Score for Sport and Activities of Daily Living to Modified Harris Hip Score and Hip Outcome Score in Patients Undergoing Arthroscopic Hip Surgery [J]. *The American Journal of Sports Medicine*, 2019, 47 (11): 2646-2650.
- [7] Sutherland C J, Wilde A H, Borden L S, et al. A ten-year follow-up of one hundred consecutive Muller curved-stem total hip-replacement arthroplasties [J]. *J Bone Joint Surg Am*, 1982, 64 (7): 970-982.
- [8] Berry D J. Epidemiology: hip and knee [J]. *Orthop Clin North Am*, 1999, 30 (2): 183-190.
- [9] Gao Minghong, Liu Anqing, Yang Limin. Analysis of the treatment of 47 cases of femoral prosthetic fractures after hip replacement [J]. *Chinese Journal of Bone and Joint Surgery*, 2019, 12 (1): 45-48.
- [10] Lindahl H, Malchau H, Herberts P, et al. Periprosthetic femoral fractures classification and demographics of 1049 periprosthetic femoral fractures from the Swedish National Hip Arthroplasty Register [J]. *J Arthroplasty*, 2005, 20 (7): 857-865.
- [11] Liu Chuangxin, Dong Wei, Zhang Tianyi, et al. Surgical treatment of Vancouver B type prosthetic fractures after artificial hip replacement [J]. *Chinese Journal of Emergency Resuscitation and Disaster Medicine*, 2019, 14 (11): 1071-1074.
- [12] Moazen M, Mak J H, Etchells L W, et al. Periprosthetic femoral fracture--a biomechanical comparison between Vancouver type B1 and B2 fixation methods [J]. *J Arthroplasty*, 2014, 29 (3): 495-500.
- [13] Demos H A, Briones M S, White P H, et al. A biomechanical comparison of periprosthetic femoral fracture fixation in normal and osteoporotic cadaveric bone [J]. *J Arthroplasty*, 2012, 27 (5): 783-788.
- [14] Della R G, Leung K S, Pape H C. Periprosthetic fractures: epidemiology and future projections [J]. *J Orthop Trauma*, 2011, 25 Suppl 2: S66-S70.
- [15] Lee J M, Kim T S, Kim T H. Treatment of Periprosthetic Femoral Fractures Following Hip Arthroplasty [J]. *Hip Pelvis*, 2018, 30 (2): 78-85.
- [16] Zhang Feng, Zhou Jiansheng, Wang Zhiyan, et al. Progress in the treatment of Vancouver B-type femoral prosthetic fractures [J]. *Journal of Traumatic Surgery*, 2015 (1): 85-88.
- [17] Solgaard S, Kjersgaard A G. Increased risk for early periprosthetic fractures after uncemented total hip replacement [J]. *Dan Med J*, 2014, 61 (2): A4767.
- [18] Klein G R, Parvizi J, Rapuri V, et al. Proximal femoral replacement for the treatment of periprosthetic fractures [J]. *J Bone Joint Surg Am*, 2005, 87 (8): 1777-1781.
- [19] Lee G C, Nelson C L, Virmani S, et al. Management of periprosthetic femur fractures with severe bone loss using impaction bone grafting technique [J]. *J Arthroplasty*, 2010, 25 (3): 405-409.
- [20] Rupperecht M, Sellenschloh K, Grossterlinden L, et al. Biomechanical evaluation for mechanisms of periprosthetic femoral fractures [J]. *J Trauma*, 2011, 70 (4): E62-E66.
- [21] Chatziagorou G, Lindahl H, Karrholm J. Surgical treatment of Vancouver type B periprosthetic femoral fractures: patient characteristics and outcomes of 1381 fractures treated in Sweden between 2001 and 2011 [J]. *Bone Joint J*, 2019, 101-B (11): 1447-1458.